XI CURSO AVANZADO DE SARCOMAS GEIS 2019

Madrid, 9 y 10 de mayo de 2019

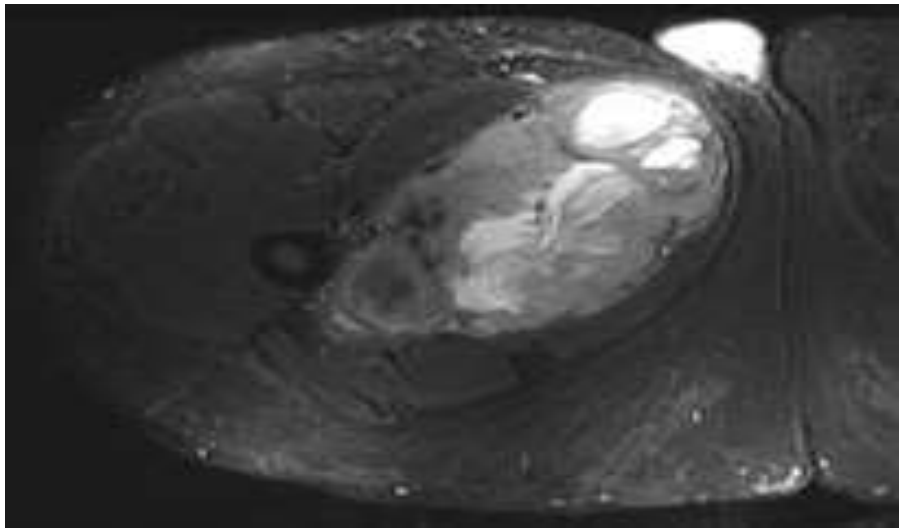

SARCOMAS DE PARTES BLANDAS:

SPB localizado

Dr. J. Martínez Trufero, Hospital Univ. Miguel Servet, Zaragoza
Dr. A. Casado, Hospital Clínico San Carlos, Madrid

ESQUEMA DE PRESENTACIÓN

1. Introducción/ presentación del caso resumido
2. Diagnóstico radiológico .
3. Diagnóstico histológico/molecular.
4. Tratamiento preoperatorio:
   - QT.
   - RT .
5. Evaluación de respuesta radiológica
6. Tratamiento quirúrgico.
7. Evaluación de respuesta patológica
8. Control y seguimiento posterior.

Clin Transl Oncol (2016) 18:1213–1220
DOI 10.1007/s12094-016-1574-1

CLINICAL GUIDES IN ONCOLOGY

SEOM Clinical Guideline of management of soft-tissue sarcoma (2016)

A. López-Pousa[1] · J. Martin Broto[2] · J. Martinez Trufero[3] · I. Sevilla[4] · C. Valverde[5] · R. Alvarez[6] · J. A. Carrasco Alvarez[7] · J. Cruz Jurado[8] · N. Hindi[2] · X. Garcia del Muro[9]

- Reconocer signos de alarma antes del diagnóstico.
- Referencia a centros especializados.
- Criterios de calidad de Centros de referencia.
- Calidad biopsia inicial.
- Patólogo experto.
- Radicalidad de cirugía inicial.
- Criterios de RT y QT pre y postoperatoria.

1. PRESENTACIÓN DEL CASO

ANAMNESIS

Paciente de 39 años.

Antecedentes personales:

- Obesidad .
- SAOS severo (BIPAP).
- Estenosis del canal L3-S1 (artrodesis en oct 2012).

En Mayo 2013: Consulta por presentar una tumoración en raíz de muslo derecho de crecimiento rápido, de 1 mes de evolución.

2.DIAGNÓSTICO RADIOLÓGICO

Estudio imagen local

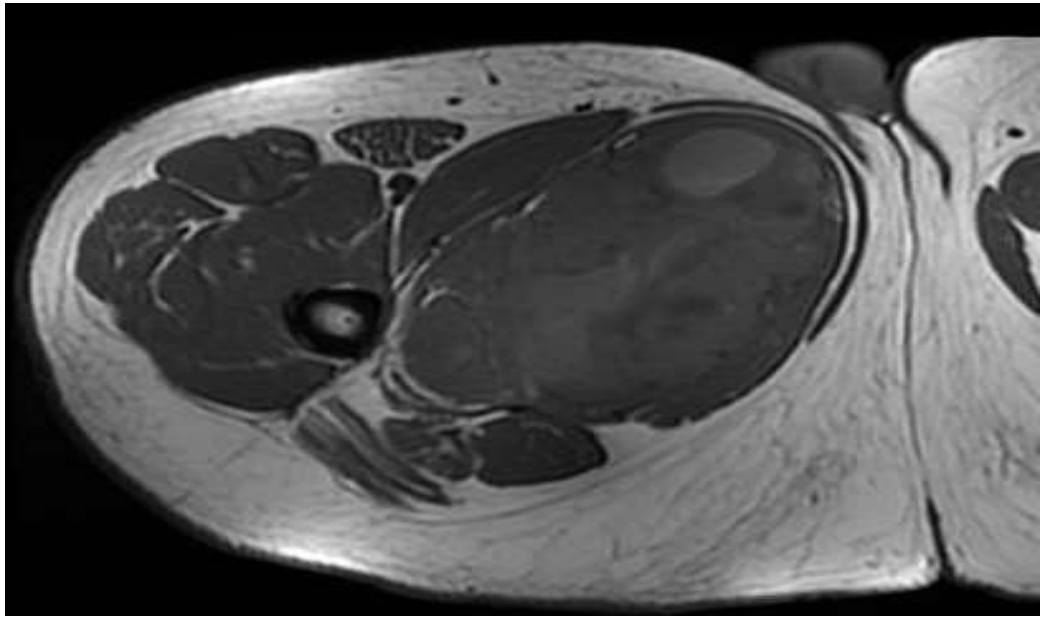

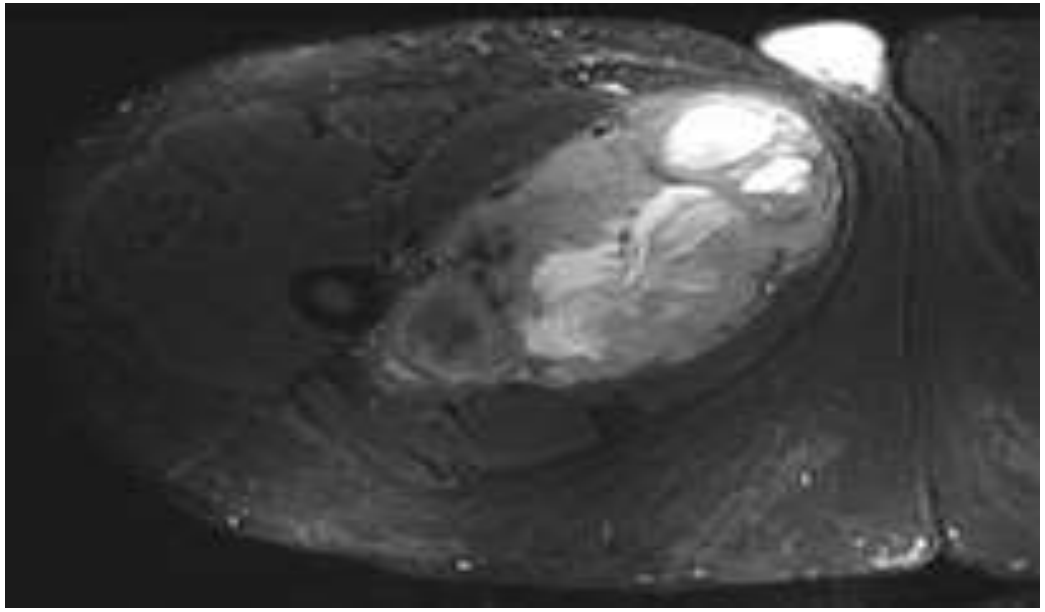

RNM (29/7/13): Tumoración de partes blandas de 22x18x10cm dentro del compartimento adductor del muslo:

- **Zonas necrótico / hemorrágicas centrales (Triple signo).**
- **Relaciones vasculares y hueso**

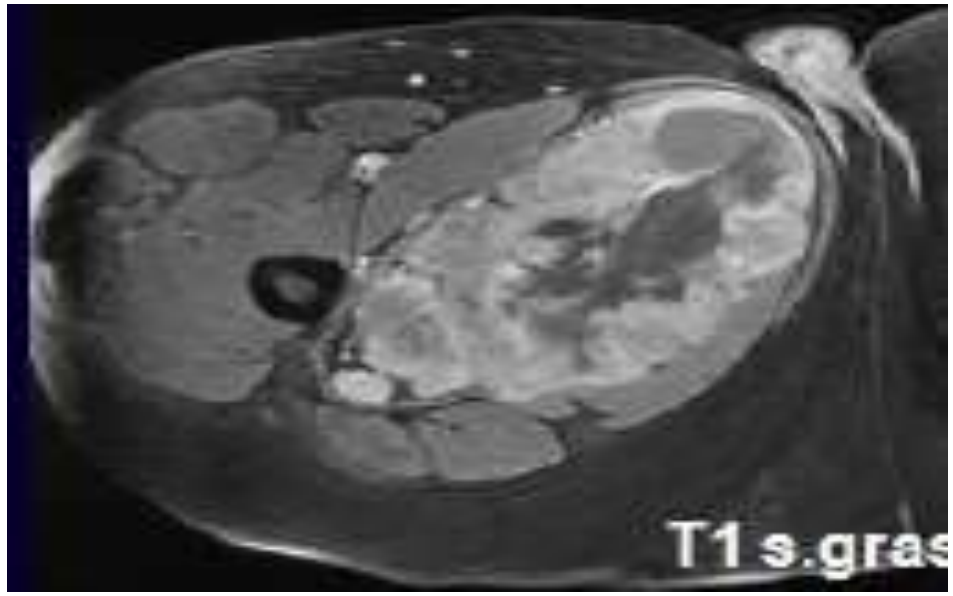

Estudio imagen local

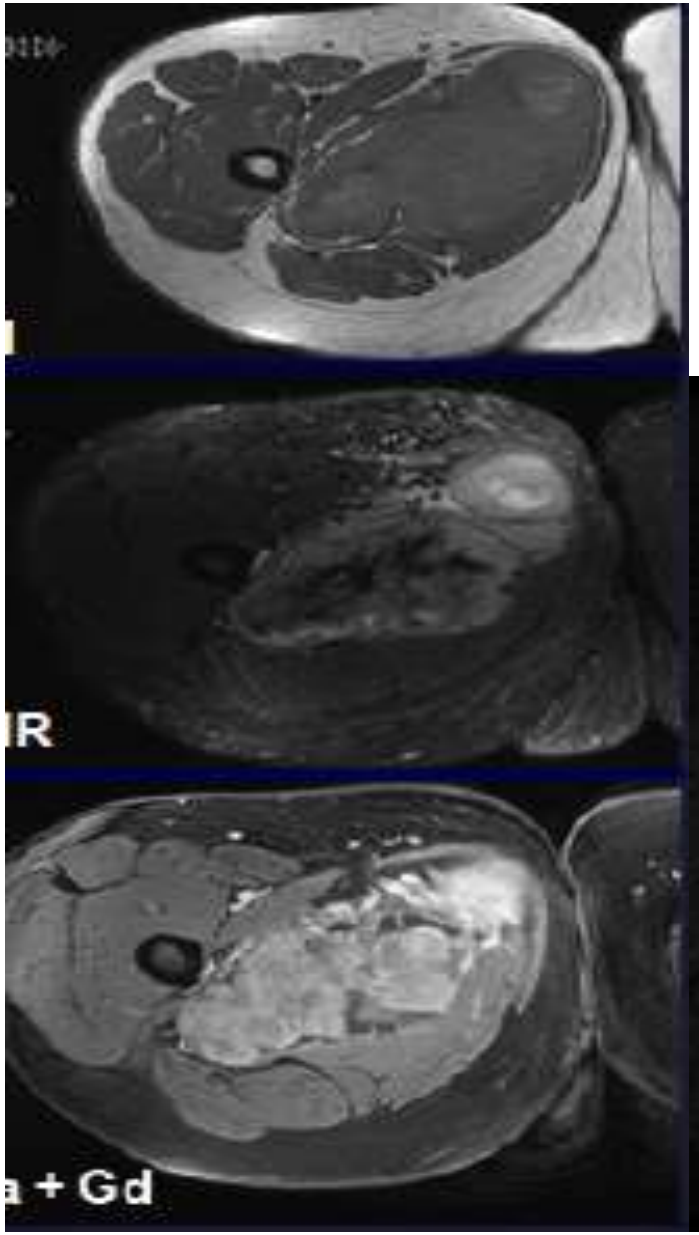

- Zonas necrótico / hemorrágicas centrales (Triple signo).
- Áreas de hiposeñal en todas las secuencias:
  - Calcificaciones
  - Vascularización
  - Fibrosis muy colagenizada

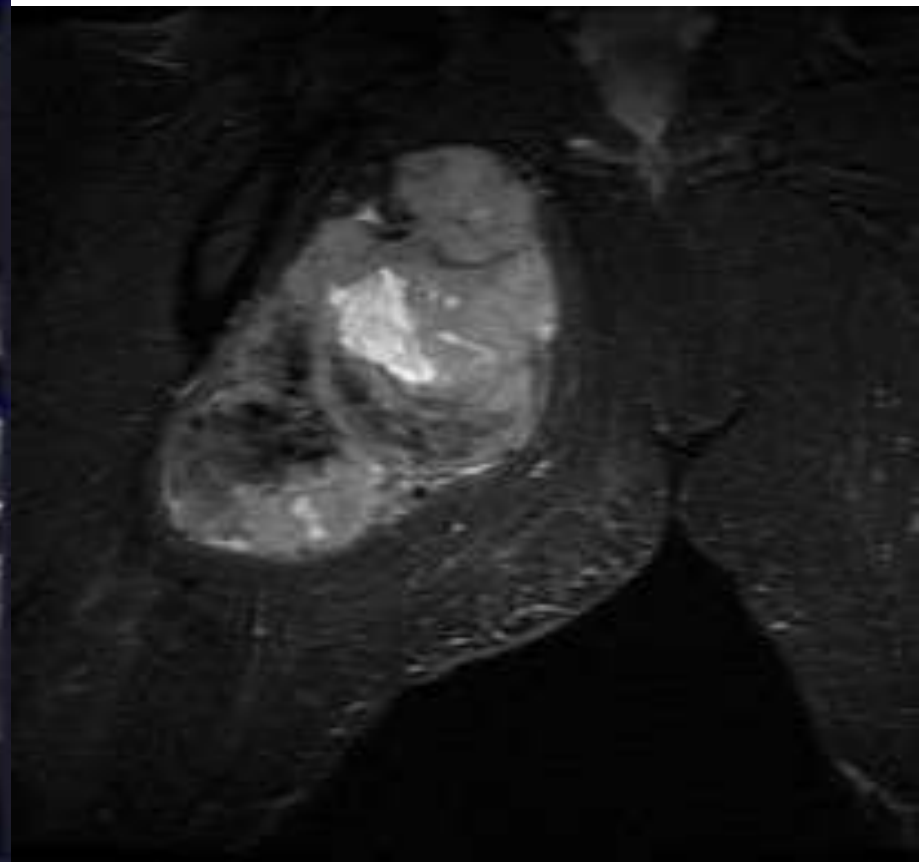

Sospecha de SPB:

- Edad (corte 35a)
- Tamaño >5cm
- Localización (prof)
- Características RM
  - Heterogéneo
  - Sangre
  - Triple señal

ESTUDIO DE EXTENSIÓN

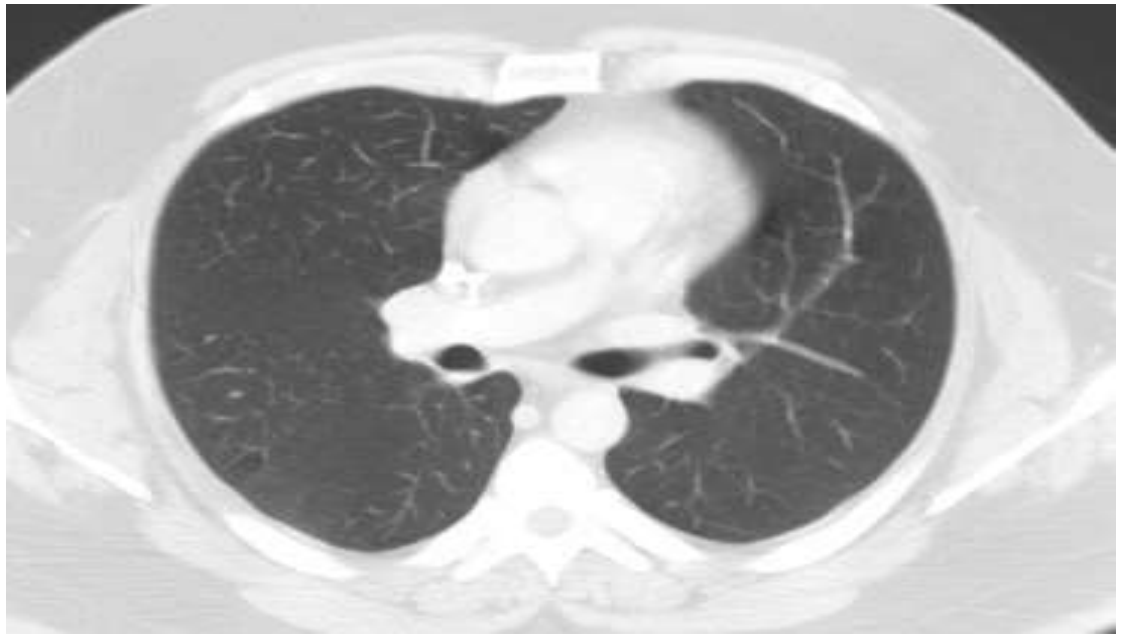

TAC tórax-abdomen

- **sin hallazgos en pulmón y abdomen.**
- **sin signos de metástasis óseas ¿?**

Estadiaje AJCC 8ª Ed
T4 N0 M0 G?

Estudio Funcional

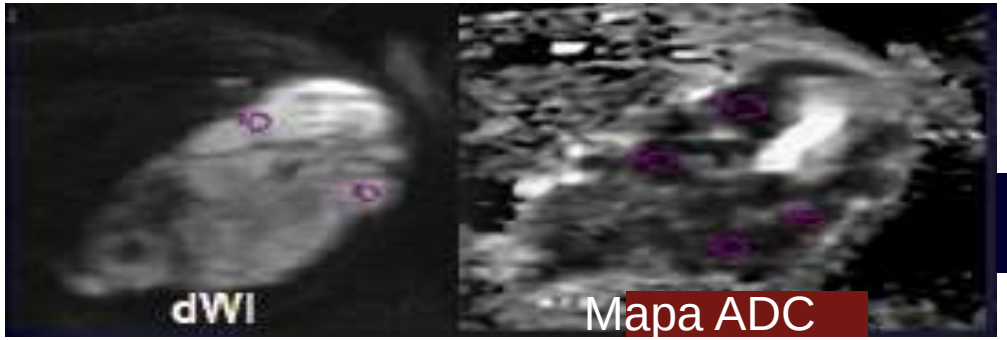

Difusión

CDAminimo** (ROI zonas sólidas): **0,85
CDA medio** (ROI toda la lesión): **1,53

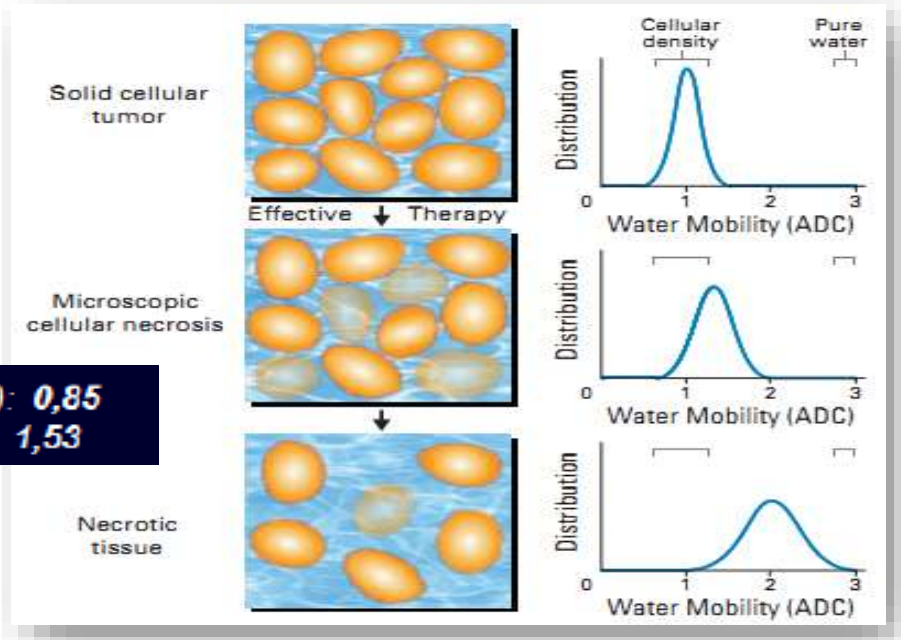

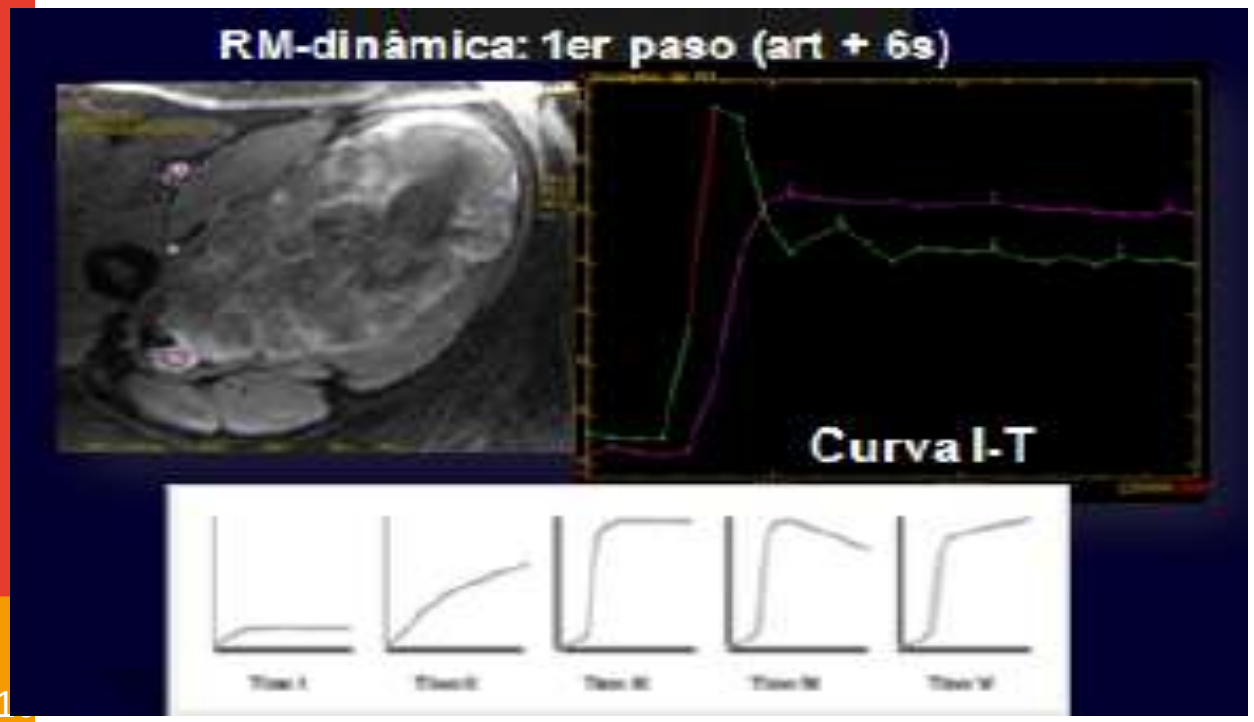

- **Estudio dinámico con cte. (RMD):** sec. multifásica ultrarrápida (3-5 min, fases 5-8seg), tras adm. Gd. Procesado, ROI zonas +vasc. y obtención curva I-S.
- **Valora perfil temporal captación (info. angiogénesis / vascularización (flujo, vol., perm. capilar y perfusión)**
- ***Zonas amplias de realce precoz (1er paso). ROI con curva paralela arteria, ascenso rápido y meseta (tipo 3): tm viable muy vascularizado***

***Sospecha M** (aunque hay solap. B-M, mixoides ↑CDA)*
Info. estudio basal previo a QT

3.DIAGNÓSTICO PATOLÓGICO (Histología, IHQ, patología molecular)

Planificación: biopsia

- Octubre 2013: Biopsia abierta por cara medial.
  - Sin isquemia
  - Trans-aductores
  - Hemostasia
  - Cierre por planos
  - Sin redón

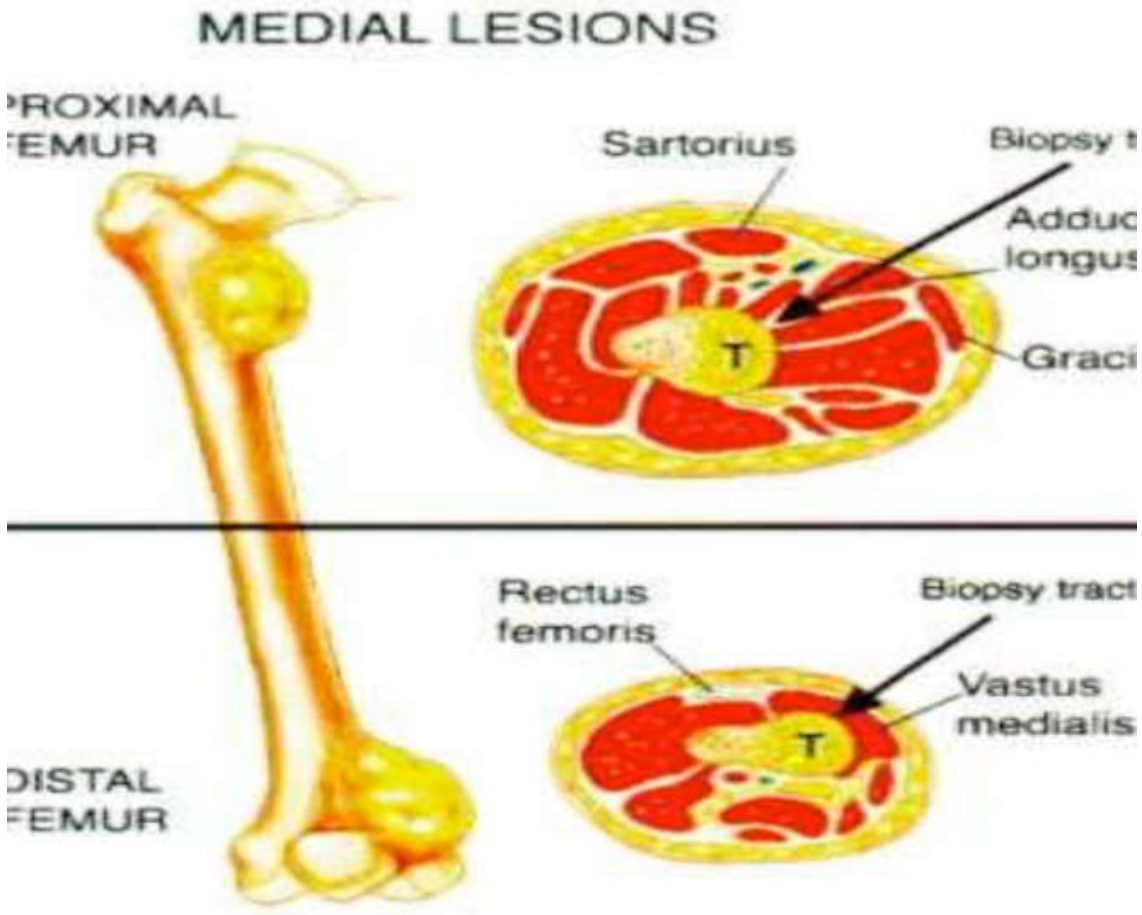

BIOPSIA PERCUTANEA

Core-needle biopsy guided by imaging (ultrasound or CT scan) is the preferred method of biopsy.
It is mandatory to avoid non-involved anatomical compartments, and it should be kept in mind that the path of the biopsy must be resected by definitive surgery.
Incisional biopsy is an alternative in the cases, where needle biopsy is not feasible.
Excisional biopsy is only acceptable for superficial lesions smaller than 3 cm in size.
Cytology could be useful in detecting recurrences, but it should not be used in the diagnosis of STS

Biopsia percutánea

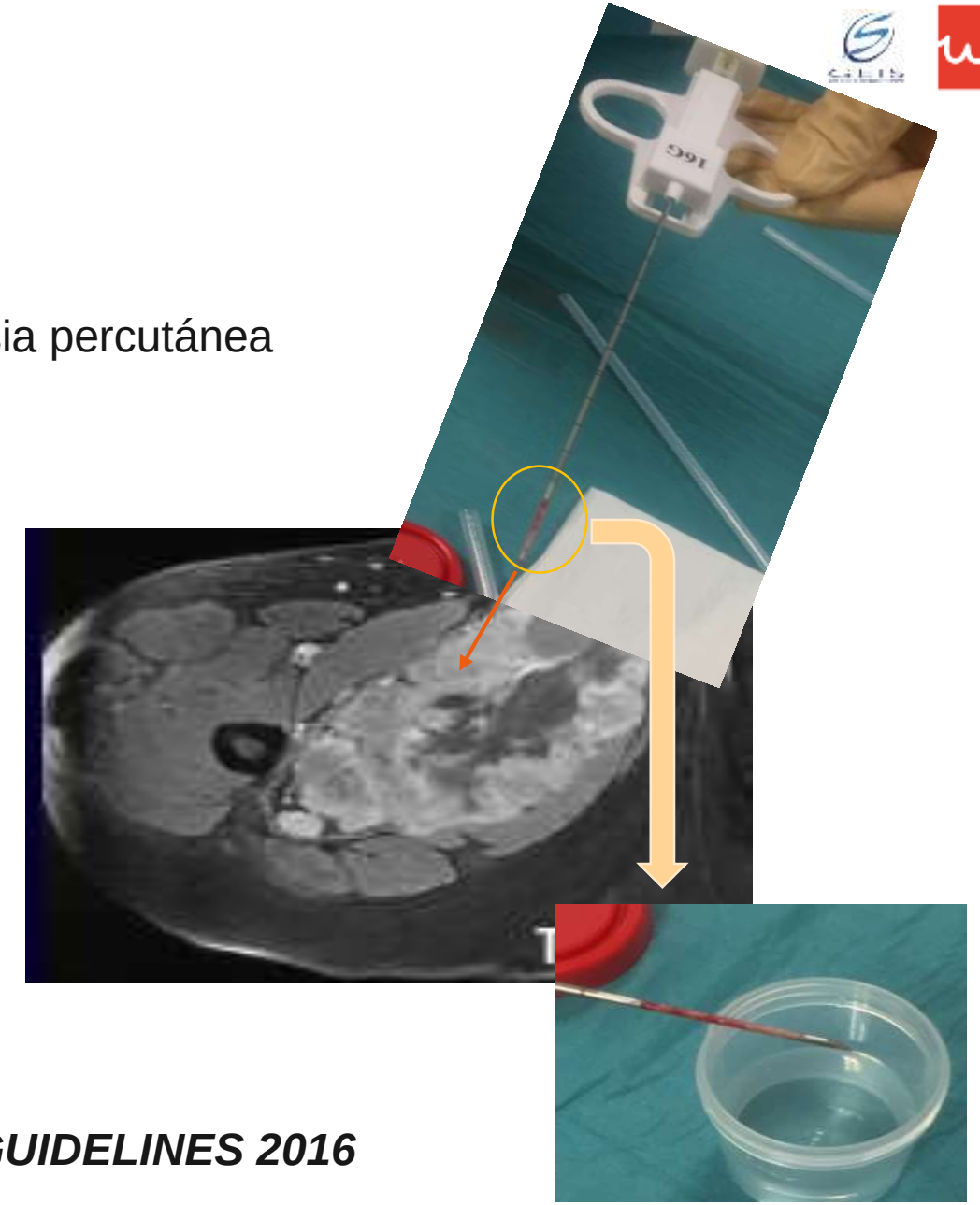

GEIS GUIDELINES 2016

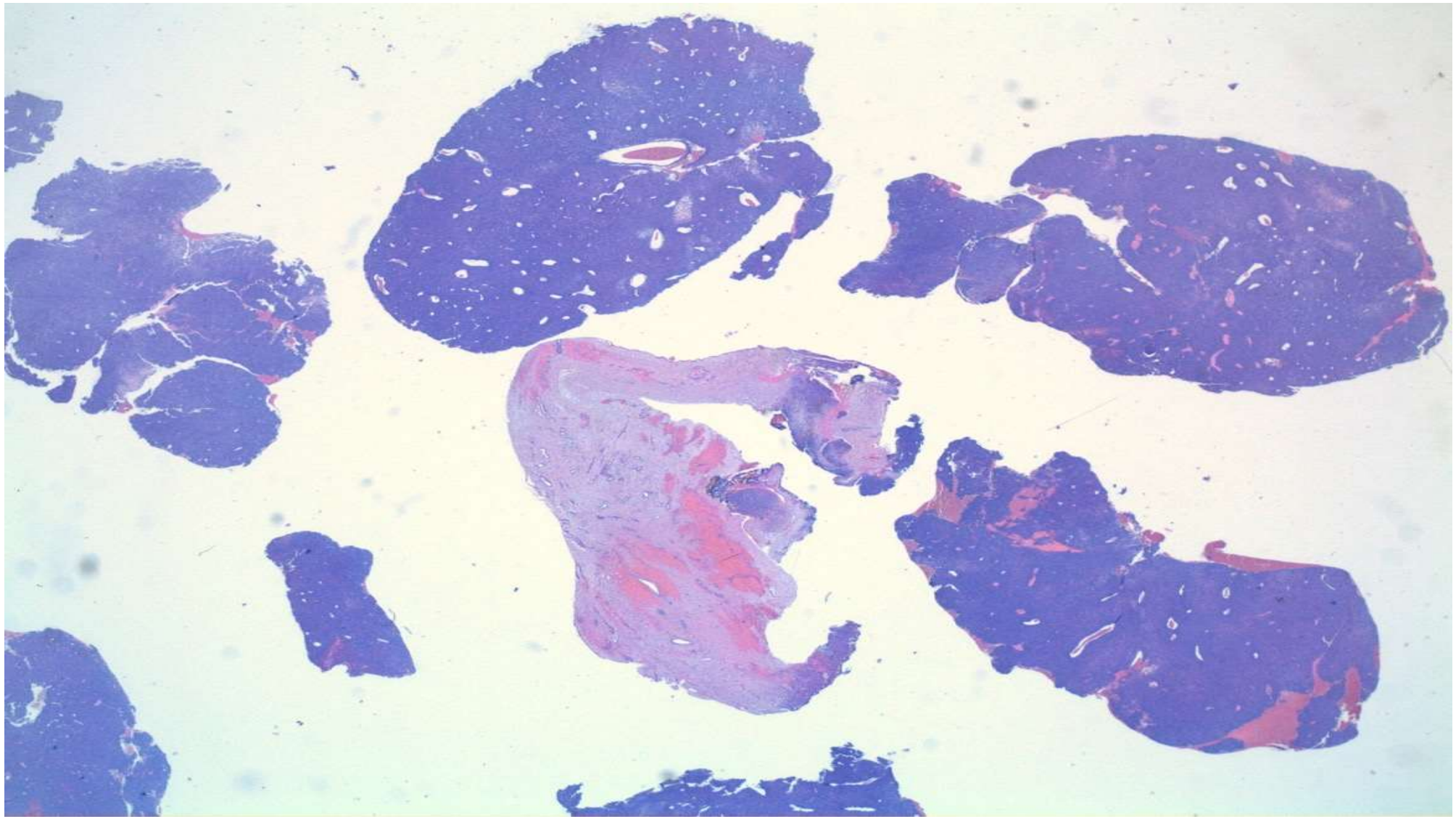

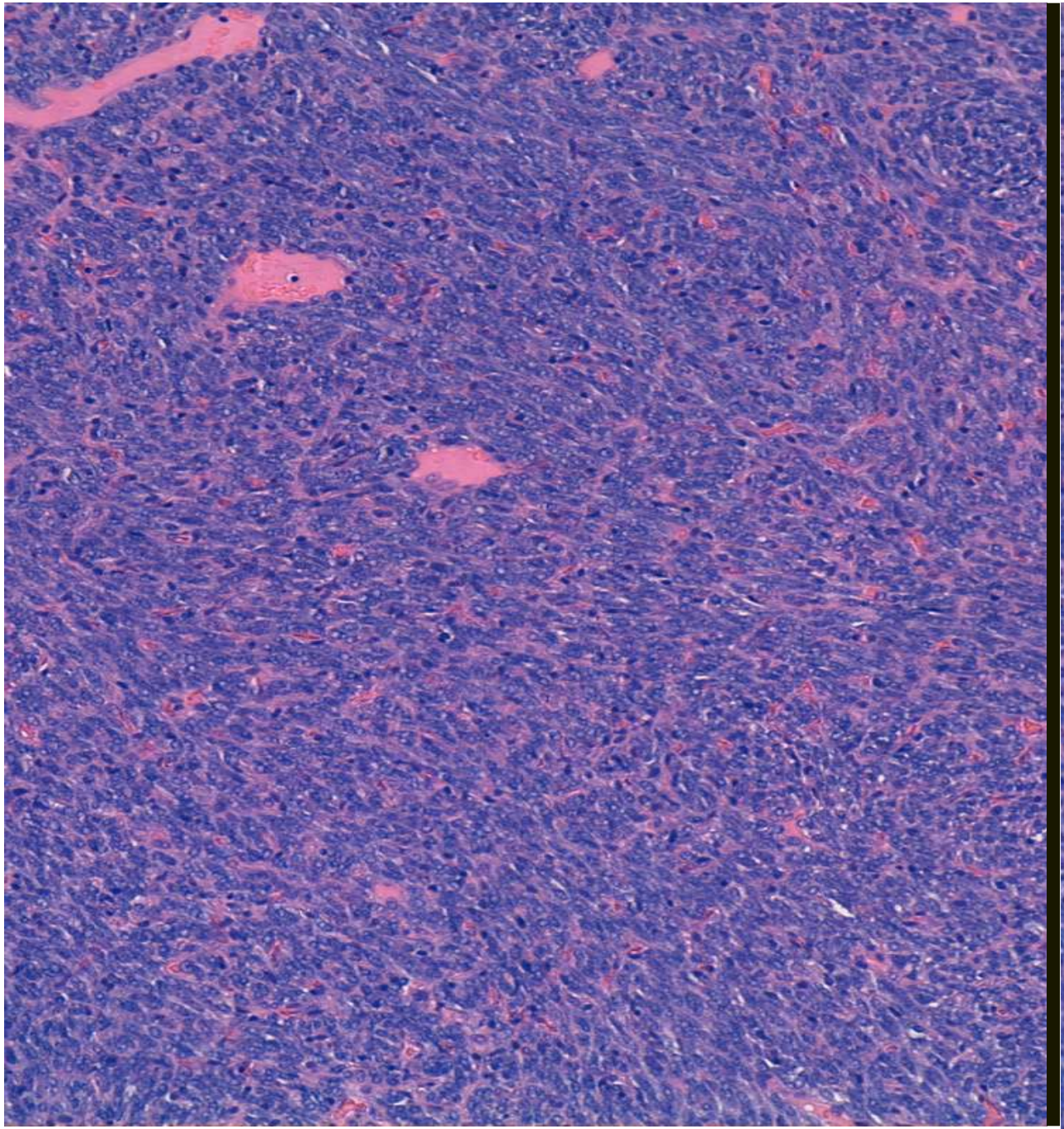

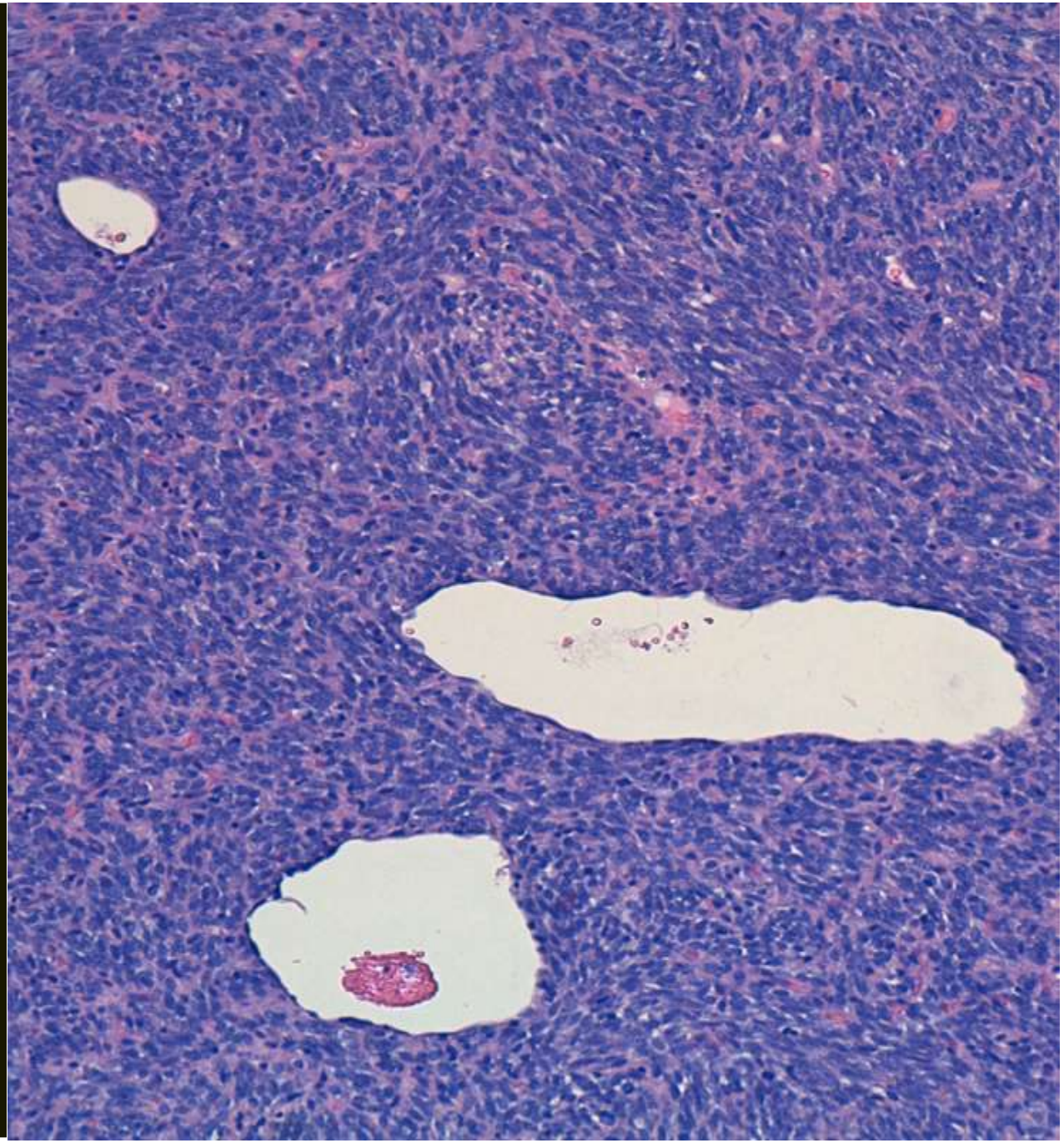

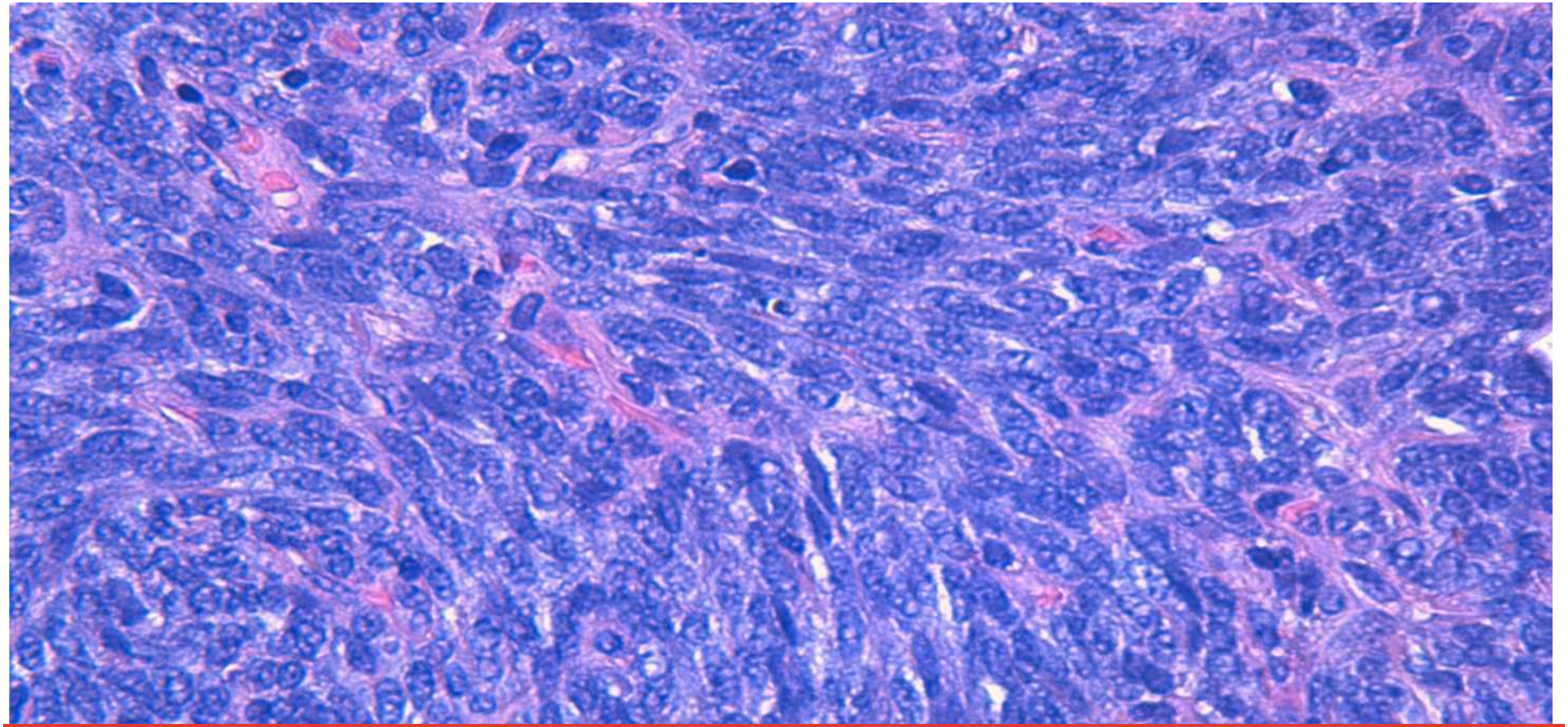

Neoplasia densamente celular constituida por células fusiformes relativamente monomorfas con atipia nuclear moderada, sin necrosis y sin un patrón bifásico desarrollado. Vascularización con patrón hemangiopericitoide focal. No se identifican microcalcificaciones. Moderada infiltración mastocitaria.

Diagnóstico diferencial morfológico: tumores fusocelulares

- Carcinoma sarcomatoide
- **Sarcomas partes blandas:**
  - Fibrosarcoma
  - Leiomiocarcoma
  - TMVNP
  - Tumor Fibroso Solitario
  - Rabdomiosarcoma fusocelular
  - ….
  - Sarcoma sinovial
    - Bifásico
    - **Monofásico**

Diagnóstico diferencial morfológico: tumores fusocelulares

- 1º Morfología (HE)
- 2º Pruebas complementarias:
  - IHQ
  - Pruebas Moleculares

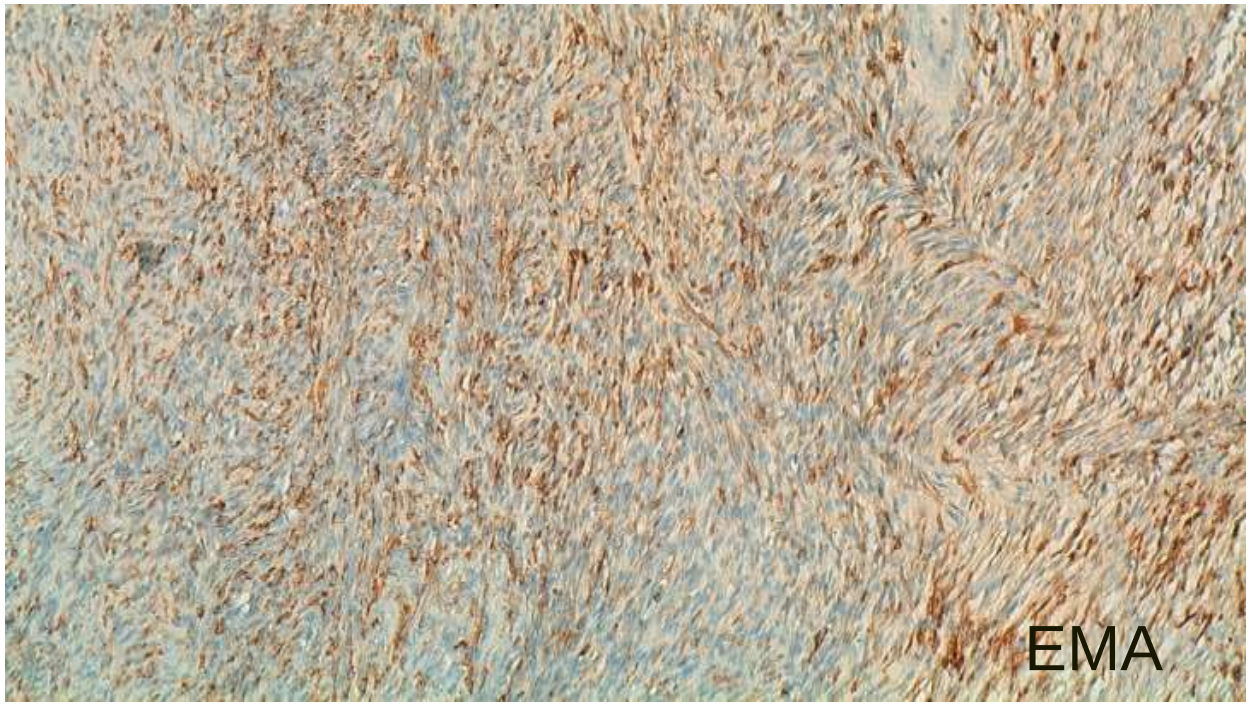
EMA

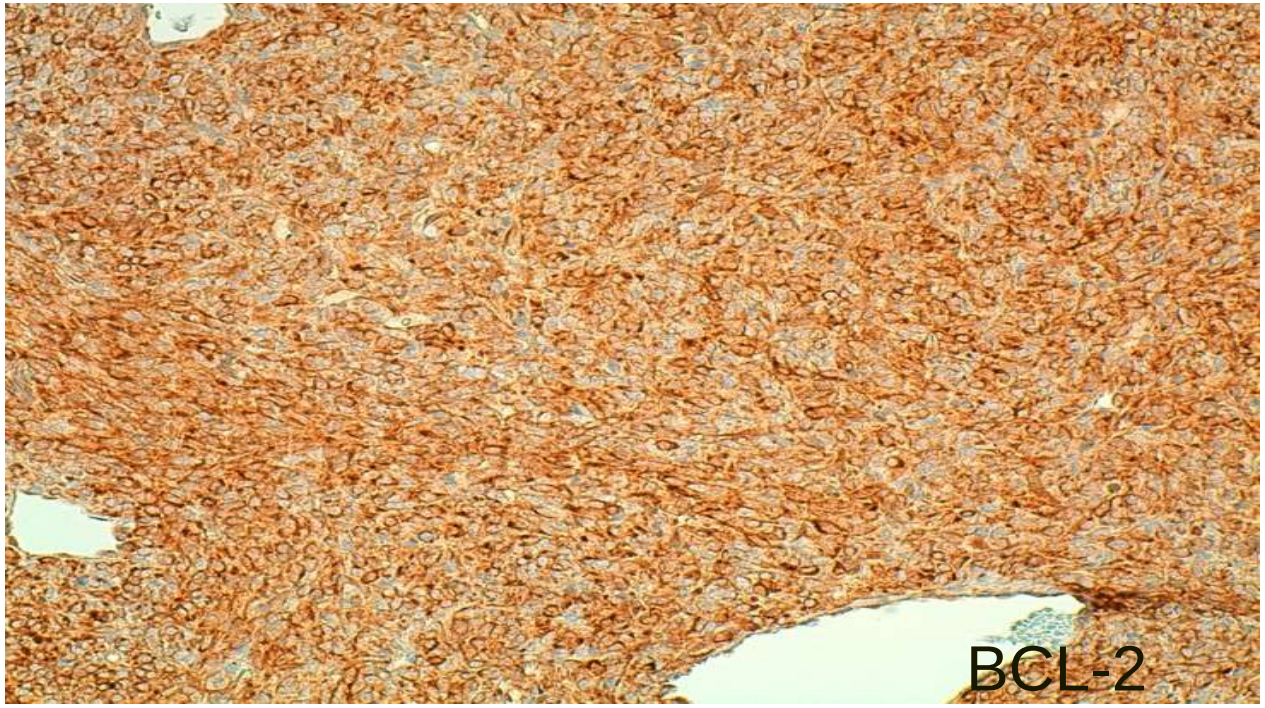
BCL-2

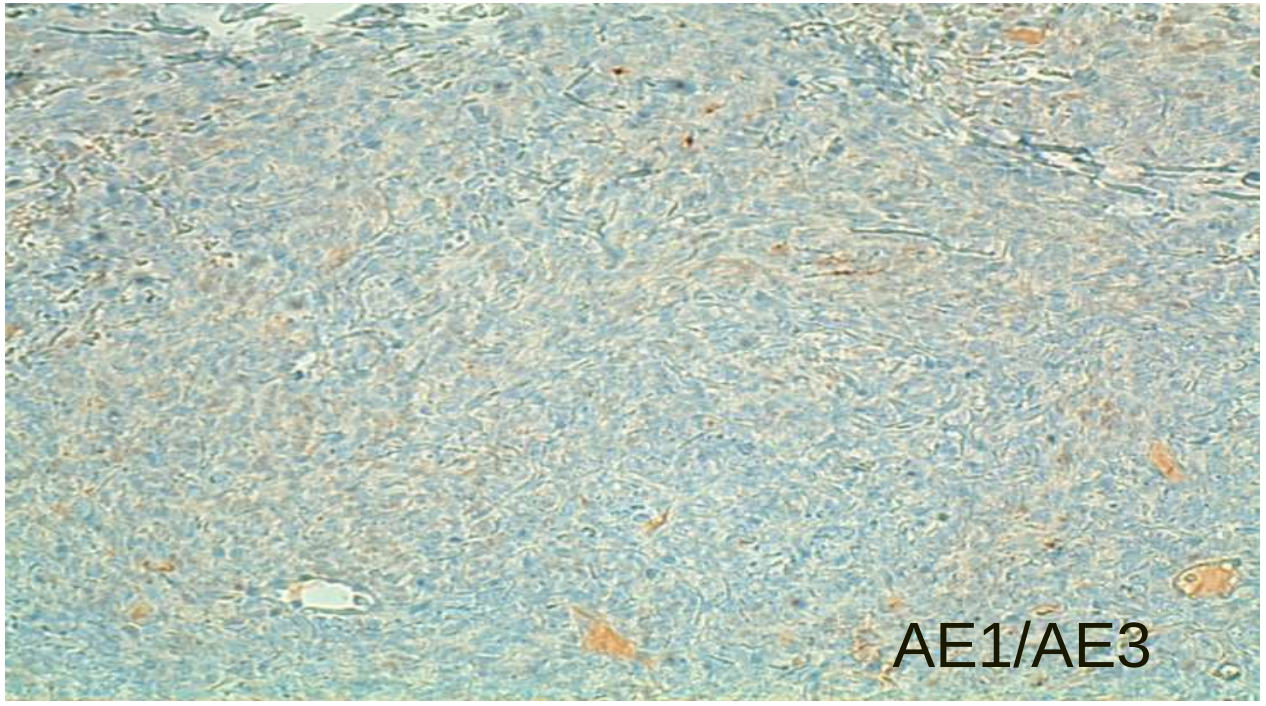
AE1/AE3

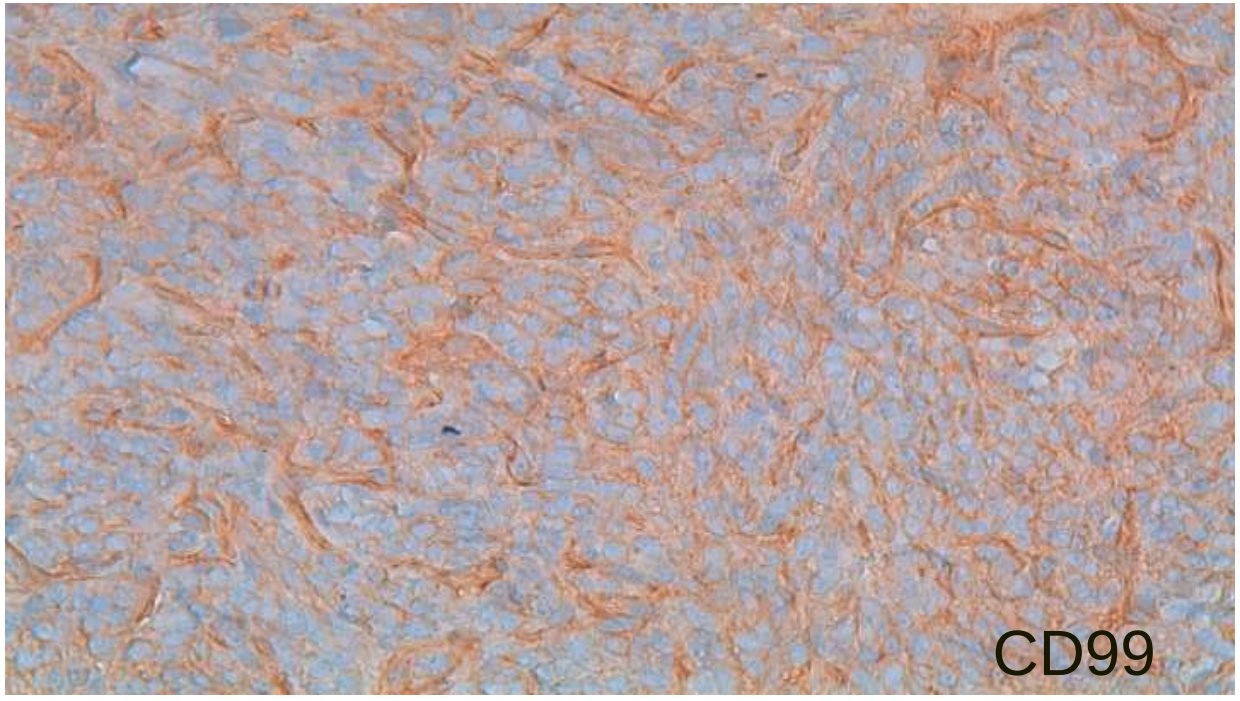
CD99

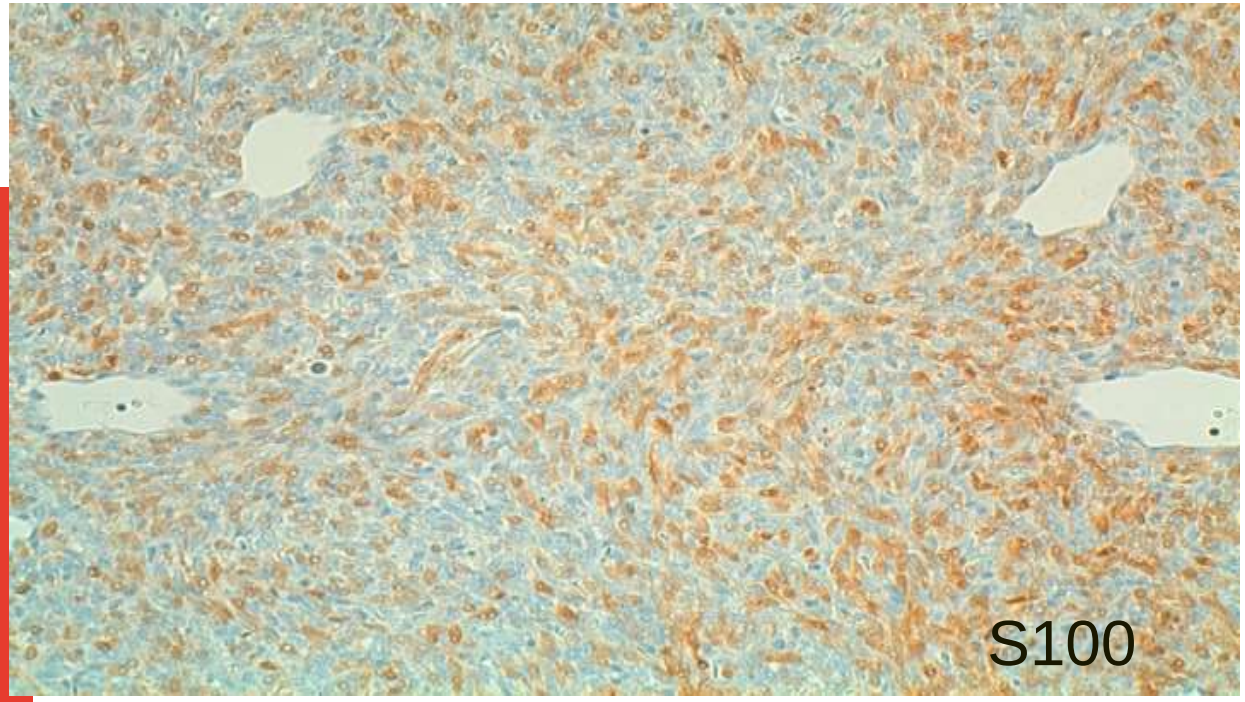
S100

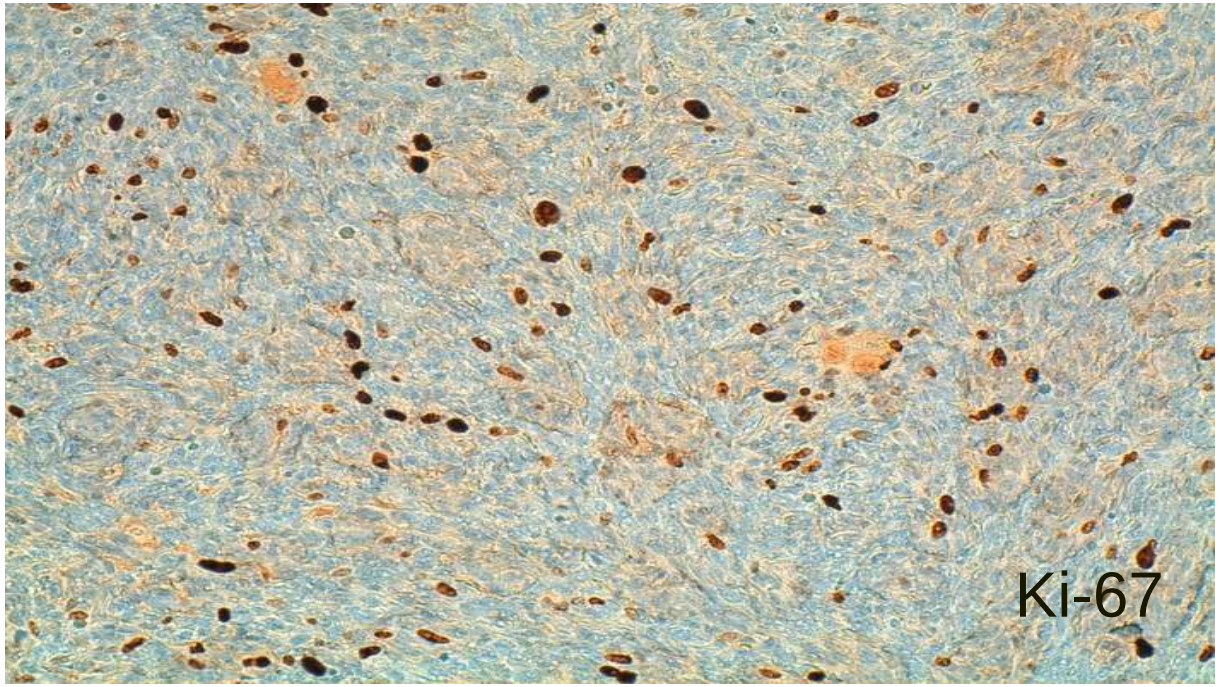
Ki-67

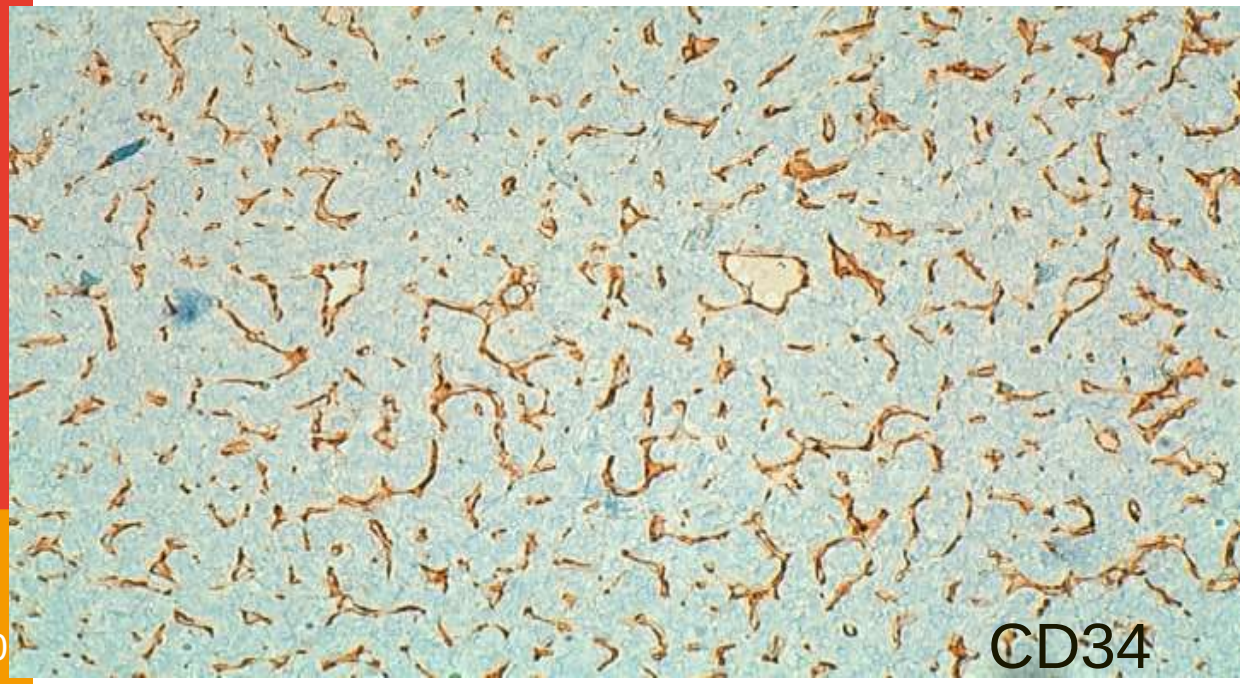
CD34

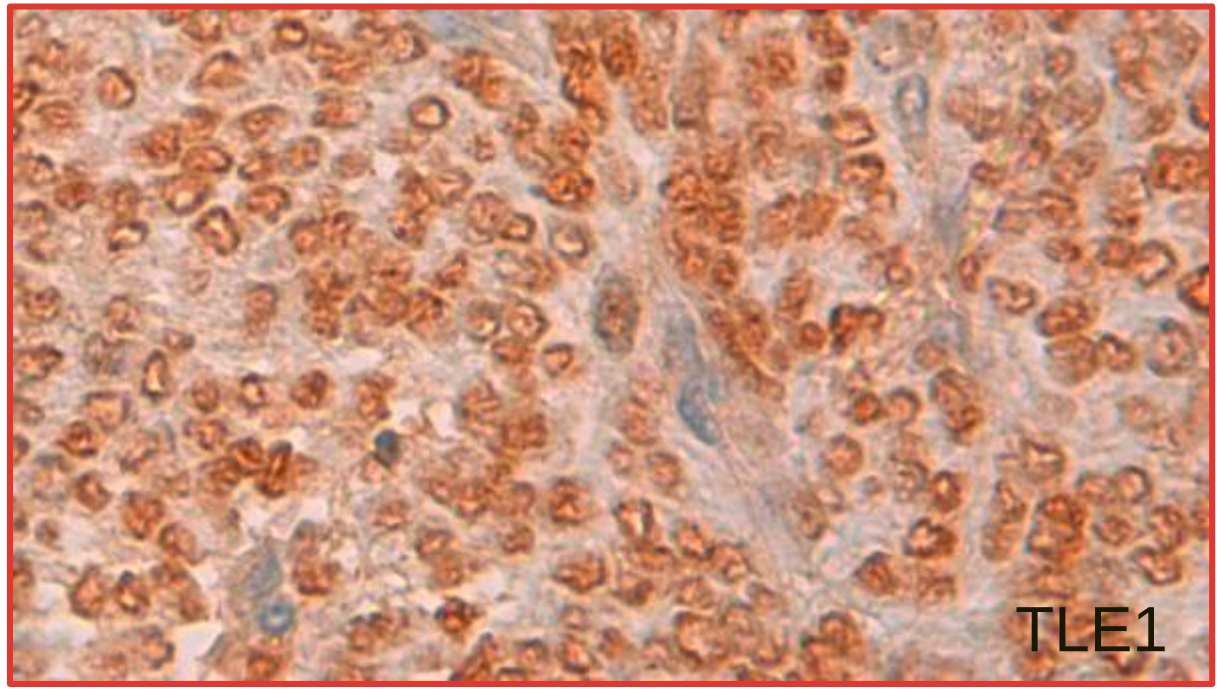
TLE1

Integración hallazgos morfológico e IHQ

- Sarcoma fusocelular
  - Inmunofenotipo epitelial
  - Expresión TLE1, CD99 y bcl2
  - Expresión S100



- **Sarcoma sinovial monofásico**
  - Translocación (X;18); Fusión génica SS18-SSX1/2
    - FISH: reordenamiento gen SS18 ??

Estudio Molecular (FISH) en este caso

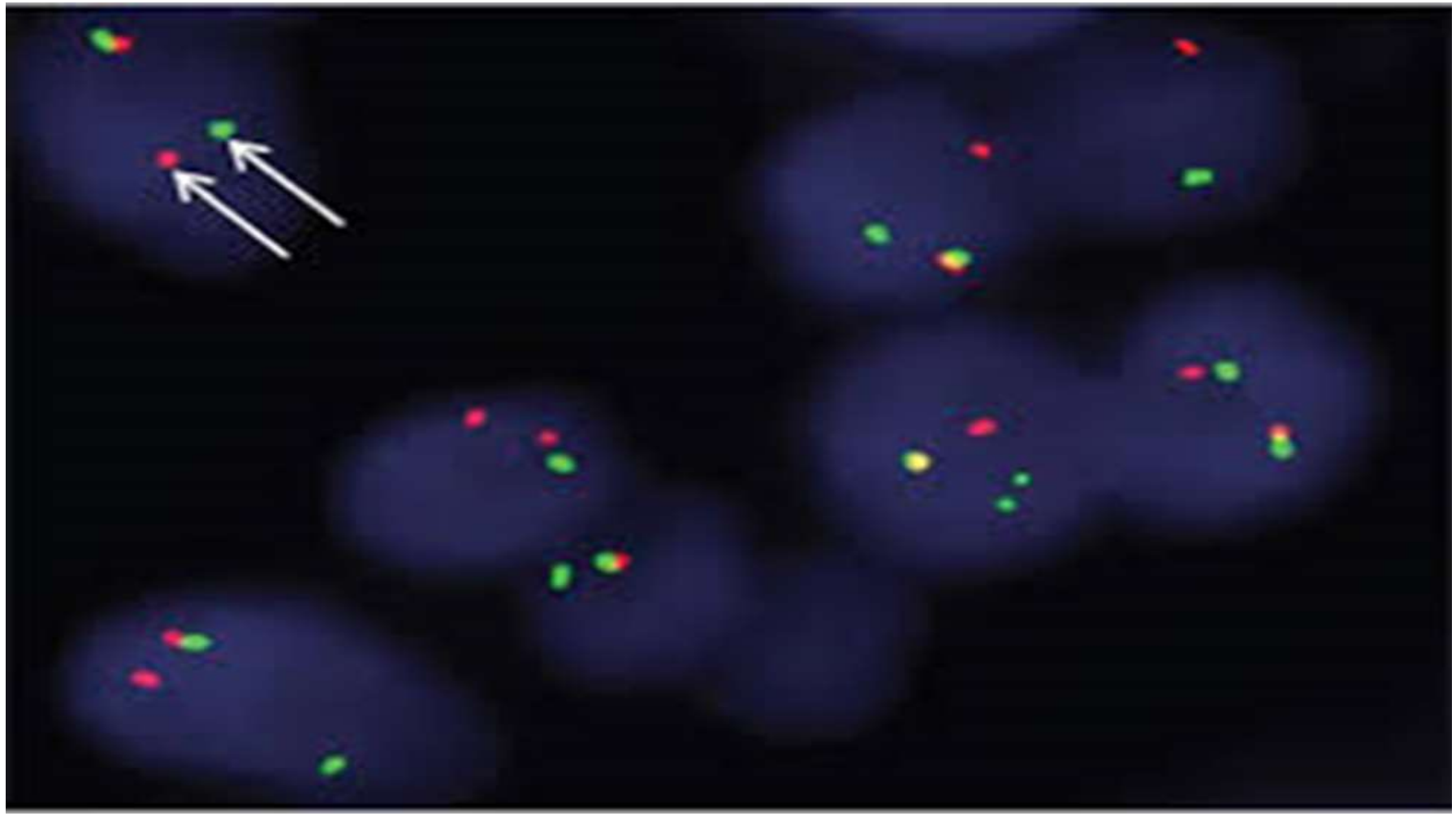

Reordenamiento del gen SS18 (breakapart)

Informe patológico (biopsia)

- Tipo histológico: Sarcoma sinovial monofásico fusocelular
- Mitosis no abundantes (<4/CGA). No se identifica necrosis
- Grado histológico (provisional): 2 (FNCLCC)
- Descripción microscópica: neoplasia densamente celular constituida por células fusiformes relativamente monomorfas con atipia nuclear moderada, sin necrosis y sin un patrón bifásico desarrollado. Vascularización con patrón hemangiopericitoide focal. No se identifican microcalcificaciones. Moderada infiltración mastocitaria.
- **IHQ**: expresión intensa de vimentina, TLE1, S100 y CD99; débil y focal para **CKAE1/AE3, CK7 y EMA.** Negatividad para CD34, CD31, desmina, HMB45, Melan A y actina de músculo liso.
- Índice proliferativo (Ki- 67): 30%
- **Patología molecular** (FISH): reordenamiento del gen SS18 (SYT)

Sarcoma Sinovial (1)

- Entidad clínica, morfológica y genética
- No se origina en tejido sinovial
  - <5% se originan en articulación o bursa
- Presenta marcadores epiteliales : “carcinoma fusocelular de partes blandas”
- Sarcoma Sinovial, término perfectamente reconocido

4.ESTADIAJE Y PRONÓSTICO

ESTADIAJE TNM (8TH EDITION)

Table 1. STS UICC TNM 8 staging system [7]

T—primary tumour

TX	Primary tumour cannot be assessed
T0	No evidence of primary tumour
Extremity and superficial trunk	
T1	Tumour 5 cm or less in greatest dimension
T2	Tumour more than 5 cm but no more than 10 cm in greatest dimension
T3	Tumour more than 10 cm but no more than 15 cm in greatest dimension
T4	Tumour more than 15 cm in greatest dimension
Retroperitoneum	
T1	Tumour 5 cm or less in greatest dimension
T2	Tumour more than 5 cm but no more than 10 cm in greatest dimension
T3	Tumour more than 10 cm but no more than 15 cm in greatest dimension
T4	Tumour more than 15 cm in greatest dimension
Head and neck	
T1	Tumour 2 cm or less in greatest dimension
T2	Tumour more than 2 cm but no more than 4 cm in greatest dimension
T3	Tumour more than 4 cm in greatest dimension
T4a	Tumour invades the orbit, skull base or dura, central compartment viscera, facial skeleton, and or pterygoid muscles
T4b	Tumour invades the brain parenchyma, encases the carotid artery, invades prevertebral muscle or involves the central nervous system by perineural spread
Thoracic and abdominal viscera	
T1	Tumour confined to a single organ
T2a	Tumour invades serosa or visceral peritoneum
T2b	Tumour with microscopic extension beyond the serosa
T3	Tumour invades another organ or macroscopic extension beyond the serosa
T4a	Multifocal tumour involving no more than two sites in one organ
T4b	Multifocal tumour involving more than two sites but not more than five sites
T4c	Multifocal tumour involving more than five sites

N—regional lymph nodes

NX	Regional lymph nodes cannot be assessed
N0	No regional lymph node metastasis
N1	Regional lymph node metastasis

M—distant metastasis

M0	No distant metastasis
M1	Distant metastasis

Stage—extremity and superficial trunk and retroperitoneum

Stage IA	T1	N0	M0	G1, GX Low Grade
Stage IB	T2, T3, T4	N0	M0	G1, GX Low Grade
Stage II	T1	N0	M0	G2, G3 High Grade
Stage IIIA	T1	N1	M0	G2, G3 High Grade
Stage IIIB	T3, T4	N0	M0	G2, G3 High Grade
Stage IIIB	Any T	N1	M0	Any G
Stage IV	Any T	Any N	M1	Any G

Stage—head and neck and thoracic and abdominal viscera

There is no stage for soft tissue sarcoma of the head and neck and thoracic and abdominal viscera.

*AJCC classifies N1 as stage IV for extremity and superficial trunk.
pTNM Pathological Classification: the pT and pN categories correspond to the T and N categories. The only pM category is pM1 (distant metastasis microscopically confirmed), pM0 is not a valid category.
AJCC, American Joint Committee on Cancer; STS, soft tissue sarcoma; TNM, tumour, node, metastasis; UICC, Union for International Cancer Control.
Reprinted from [7] with permission from John Wiley & Sons, Inc.

ESTADIAJE TNM (8TH EDITION) :

T4 N0 M0- G2

Estadio IIIB.

SUBTIPOS HISTOLÓGICOS

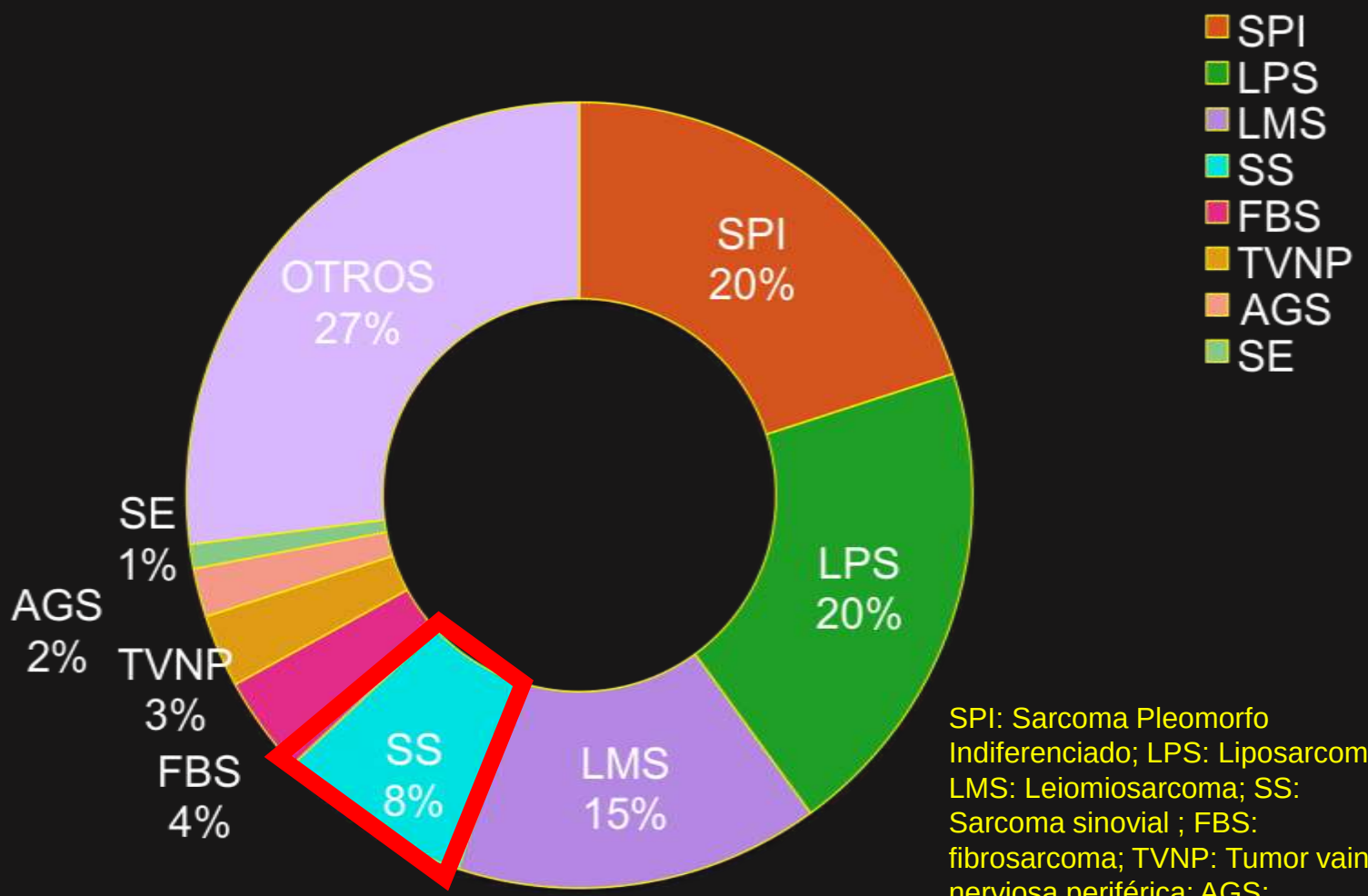

SPI: Sarcoma Pleomorfo Indiferenciado; LPS: Liposarcoma; LMS: Leiomiosarcoma; SS: Sarcoma sinovial ; FBS: fibrosarcoma; TVNP: Tumor vaina nerviosa periférica; AGS: angiosarcoma; SE: Sarcoma epitelioide.

A Synovial Sarcoma-Specific Preoperative Nomogram Supports a Survival Benefit to Ifosfamide-Based Chemotherapy and Improves Risk Stratification for Patients

Robert J. Canter,[1] Li-Xuan Qin,[2] Robert G. Maki,[3] Murray F. Brennan,[1] Marc Ladanyi,[4] and Samuel Singer[1]

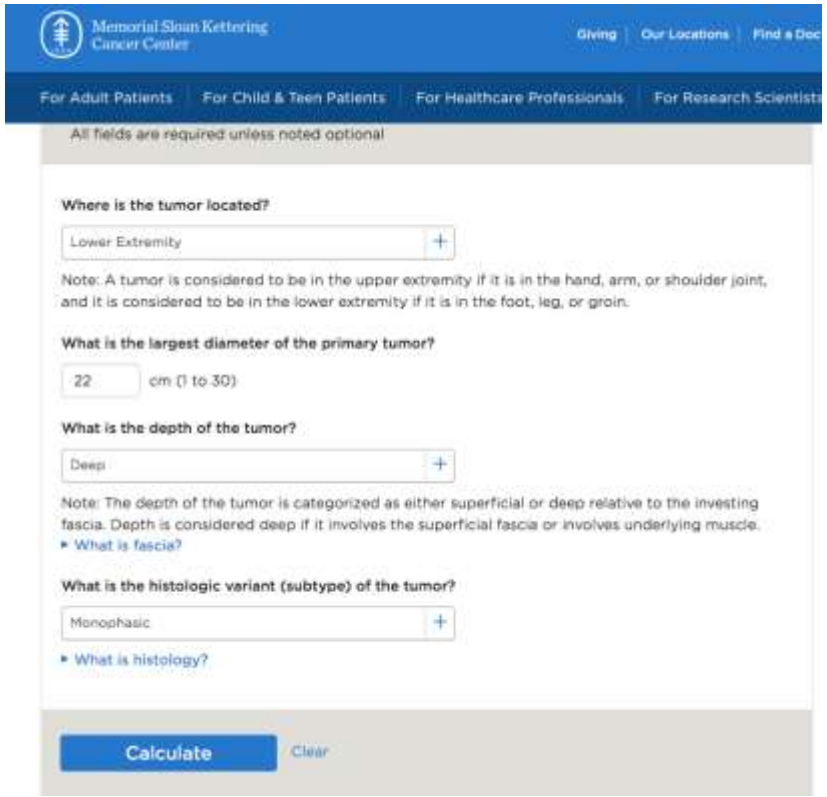

Canter RJ et al. .Clin Cancer Res. 2008 Dec 15;14(24):8191-7.

PRONÓSTICO

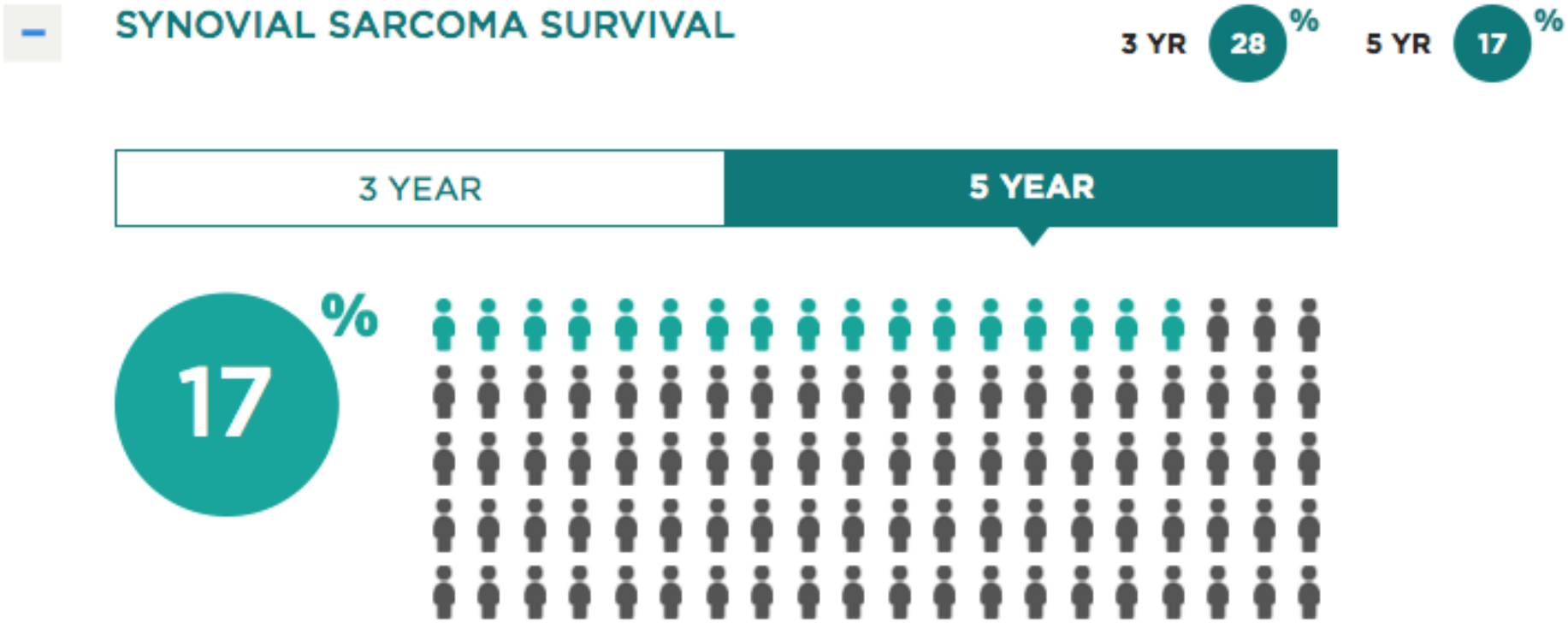

Canter RJ et al. .Clin Cancer Res. 2008 Dec 15;14(24):8191-7.

Pasquali S. J Clin Oncol 35, 2017 (suppl; abstr 11016)

ALGORITMO DE TRATAMIENTO

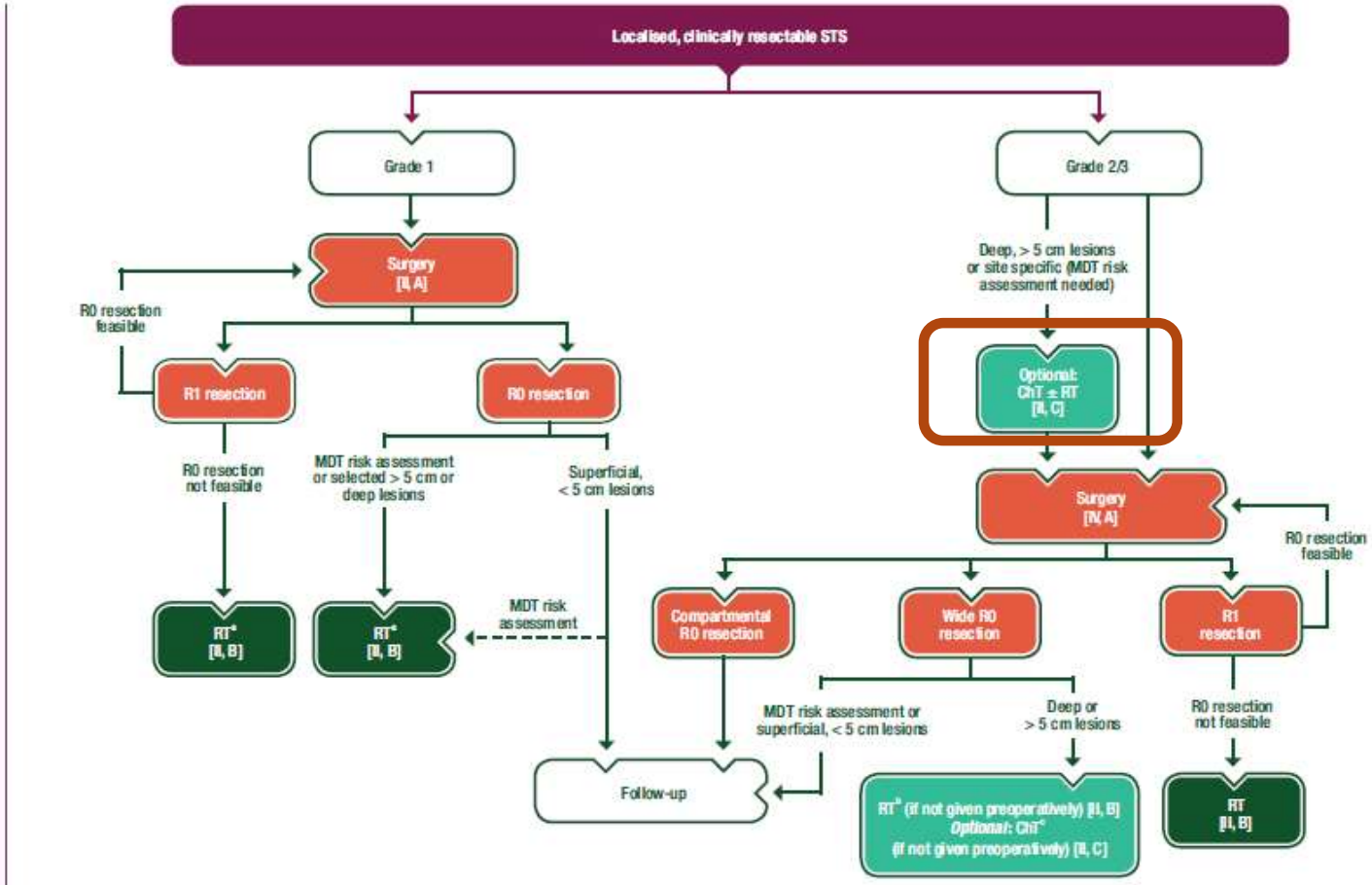

Figure 1. Management of localised, clinically resectable STS.
[a]RT can be omitted in selected cases; *optional*: isolated limb perfusion in highly selected cases.
[b]RT can be omitted in selected deep cases and added in selected superficial cases; to be administered preoperatively if problematic postoperatively.
[c]Extremity and superficial trunk, G3, deep, > 5 cm.
ChT, chemotherapy; MDT, multidisciplinary team; R0, no tumour at the margin; R1, microscopic tumour at the margin; RT, radiotherapy; STS, soft tissue sarcoma.

ESMO –EURACAN Guidelines . Casali PG. Ann Oncol. 2018 May 28.

5. TRATAMIENTO PREOPERATORIO

TRATAMIENTO

- 8/11/13- 21/12/13 : 3 ciclos de QT Neadyuvante con Ifosfamida-Epirrubicina.
- 11/12/2013 al 23/1/2014: Tratamiento RT neoadyuvante. 54 Gy .
- 13/2/2014 : exéresis quirúrgica.

TRATAMIENTO PREOPERATORIO: QT

¿POR QUÉ QT ? ¿ QUÉ ESQUEMA ?

Metaanálisis 2008

A Systematic Meta-Analysis of Randomized Controlled Trials of Adjuvant Chemotherapy for Localized Resectable Soft-Tissue Sarcoma

Nabeel Pervaiz[1]
Nigel Colterjohn, MD[2†]
Forough Farrokhyar, MPhil, PhD[2]
Richard Tozer, MD, PhD[3]
Alvaro Figueredo, MD[3]
Michelle Ghert, MD[2]

[1] University of Waterloo, Waterloo, Ontario, Canada.

[2] Department of Surgery, McMaster University and Hamilton Health Sciences, Juravinski Cancer

BACKGROUND. The use of adjuvant chemotherapy to treat adults with localized resectable soft-tissue sarcoma remains controversial. The objective of this systematic review was to update the 1997 meta-analysis of randomized controlled trials (RCTs) to reassess the efficacy of doxorubicin-based chemotherapy with respect to recurrence and survival.

METHODS. A comprehensive literature search was performed to identify RCTs of adjuvant chemotherapy for adult patients diagnosed with localized resectable soft-tissue sarcoma. Two reviewers independently assessed eligibility and quality of the studies using a modified version of the Detsky Quality Scale. The outcome measures were local, distant, and overall recurrence and survival calculated through the fixed effect or random effect model.

RESULTS. Four new eligible trials were identified allowing for a total of 18 trials representing 1953 patients to be included in the analysis. The odds ratios (OR) for local recurrence was 0.73 (95% confidence interval [CI] 0.56-0.94; $P = .02$) in favor of chemotherapy. For distant and overall recurrence the OR was 0.67 (95% CI 0.56-0.82; $P = .0001$) in favor of chemotherapy. In terms of survival, doxorubicin alone had an OR of 0.84 (95% CI, 0.68-1.03; $P = .09$), which as not statistically significant. However, the OR for doxorubicin combined with ifosfamide was 0.56 (95% CI, 0.36-0.85; $P = .01$) in favor of chemotherapy.

CONCLUSIONS. This updated meta-analysis confirms the marginal efficacy of chemotherapy in localized resectable soft-tissue sarcoma with respect to local recurrence, distant recurrence, overall recurrence, and overall survival. These benefits are further improved with the addition of ifosfamide to doxorubicin-based regimens, but must be weighed against associated toxicities. *Cancer* **2008;113:573–81.** © *2008 American Cancer Society.*

18 Ensayos clínicos

1953 pacientes

5 ensayos Antraciclina-Ifosfamida

Metaanálisis 2008

Relative Risks and 95% Confidence Intervals for Local Recurrence, Distant Recurrence, Overall Recurrence, and Survival

	Local recurrence		Distant recurrence		Overall recurrence		Survival	
Treatment	RR	95% CI	RR	95% CI	RR	95% CI	RR	95% CI
Doxorubicin	0.75	0.56-1.01	0.69	0.56-0.86	0.69	0.56-0.86	0.84	0.68-1.03
Doxorubicin with ifosfamide	0.66	0.39-1.12	0.61	0.41-0.92	0.61	0.41-0.92	0.56	0.36-0.85
Combined	0.73	0.56-0.94	0.67	0.56-0.82	0.67	0.56-0.82	0.77	0.64-0.93

RR indicates relative risk, 95% CI, 95% confidence interval.

Absolute Risk Reductions and 95% Confidence Intervals for Local Recurrence, Distant Recurrence, Overall Recurrence, and Survival

	Local recurrence		Distant recurrence		Overall recurrence		Survival	
Treatment	ARR	95% CI	ARR	95% CI	ARR	95% CI	ARR	95% CI
Doxorubicin	3%	1%-7%	9%	4%-14%	9%	4%-14%	5%	6%-21%
Doxorubicin with ifosfamide	5%	1%-12%	10%	1%-19%	12%	3%-21%	11%	3%-19%
Combined	4%	0%-7%	9%	5%-14%	10%	5%-15%	6%	2%-11%

ARR indicates absolute risk reduction, 95% CI, 95% confidence interval.

IFOSFAMIDE
Response by Histology

HISTOLOGY	NO. EVAL PTS.	% OVERALL RESPONSE
Leiomyosarcoma	11	0
Neurosarcoma	7	29
Fibrosarcoma	5	80
Synovial Sarcoma	4	75
MFH	2	0
Liposarcoma	1	0
Rhabdomyosarcoma	2	50
Angiosarcoma	2	50
Unclassified	2	50

Le Cesne *et al, JCO 13:1600-1608, 1995.*

DOSE-INTENSIVE AI IN STS

RESPONSE DATA

Responses by Histology:

15/17 Synovial sarcomas	(88%)
5/6 Angiosarcomas	(83%)
22/32 MFH	(69%)
9/15 Unclassified sarcomas	(60%)
5/9 Liposarcomas	(56%)
9/18 Non-GI Leiomyosarcomas	(50%)
2/5 Neurofibrosarcomas (MPNST)	(40%)
9/20 Other histologies	(45%)

Patel 5/00

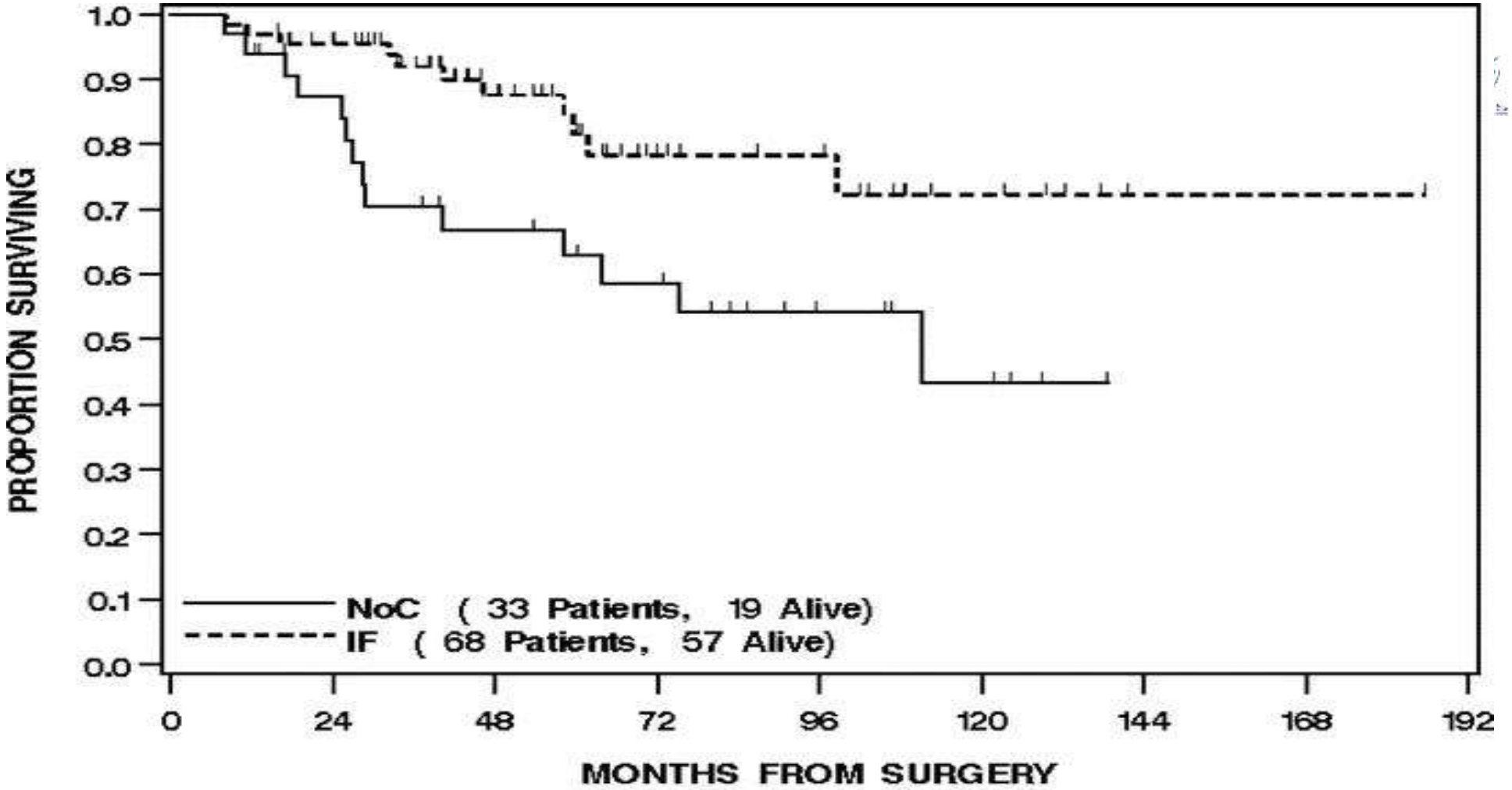

Tick mark(|) indicates last follow—up

p = 0.01

Eiber BC. Ann Surg. 2007 Jul; 246(1): 105–113.

¿POR QUÉ QT PREOPERATORIA ?

Short, Full-Dose Adjuvant Chemotherapy in High-Risk Adult Soft Tissue Sarcomas: A Randomized Clinical Trial From the Italian Sarcoma Group and the Spanish Sarcoma Group

Alessandro Gronchi, Sergio Frustaci, Mario Mercuri, Javier Martin, Antonio Lopez-Pousa, Paolo Verderio, Lidia Mariani, Pinuccia Valagussa, Rosalba Miceli, Silvia Stacchiotti, Angelo Paolo Dei Tos, Antonino De Paoli, Alessandra Longhi, Andres Poveda, Vittorio Quagliuolo, Alessandro Comandone, Paolo Giovanni Casali, and Piero Picci

RANDOMIZACIÓN

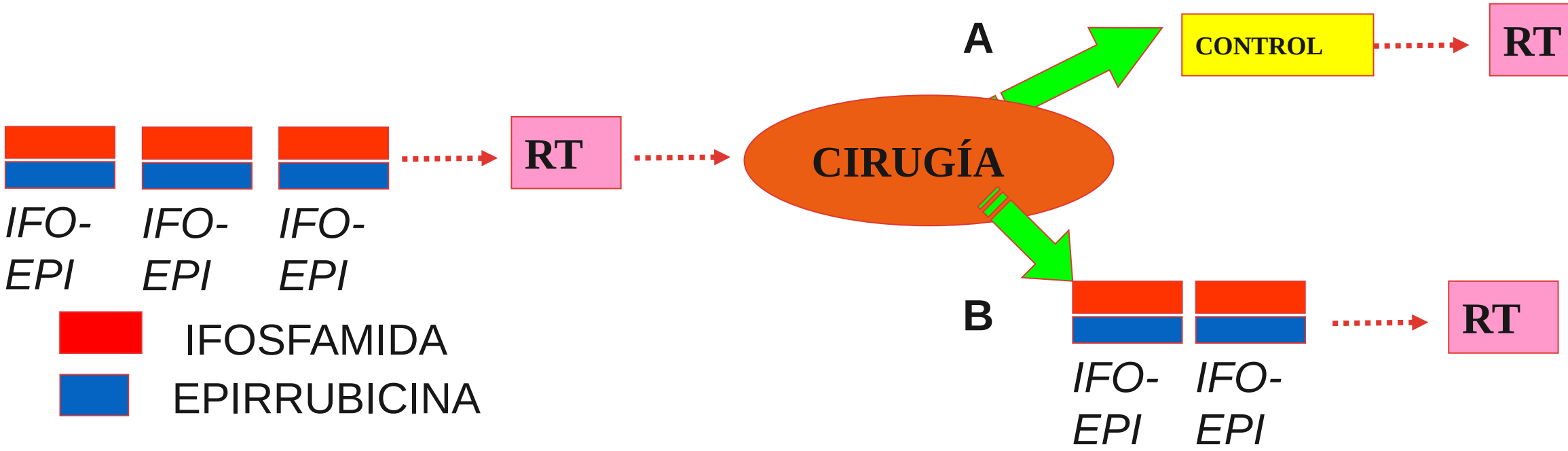

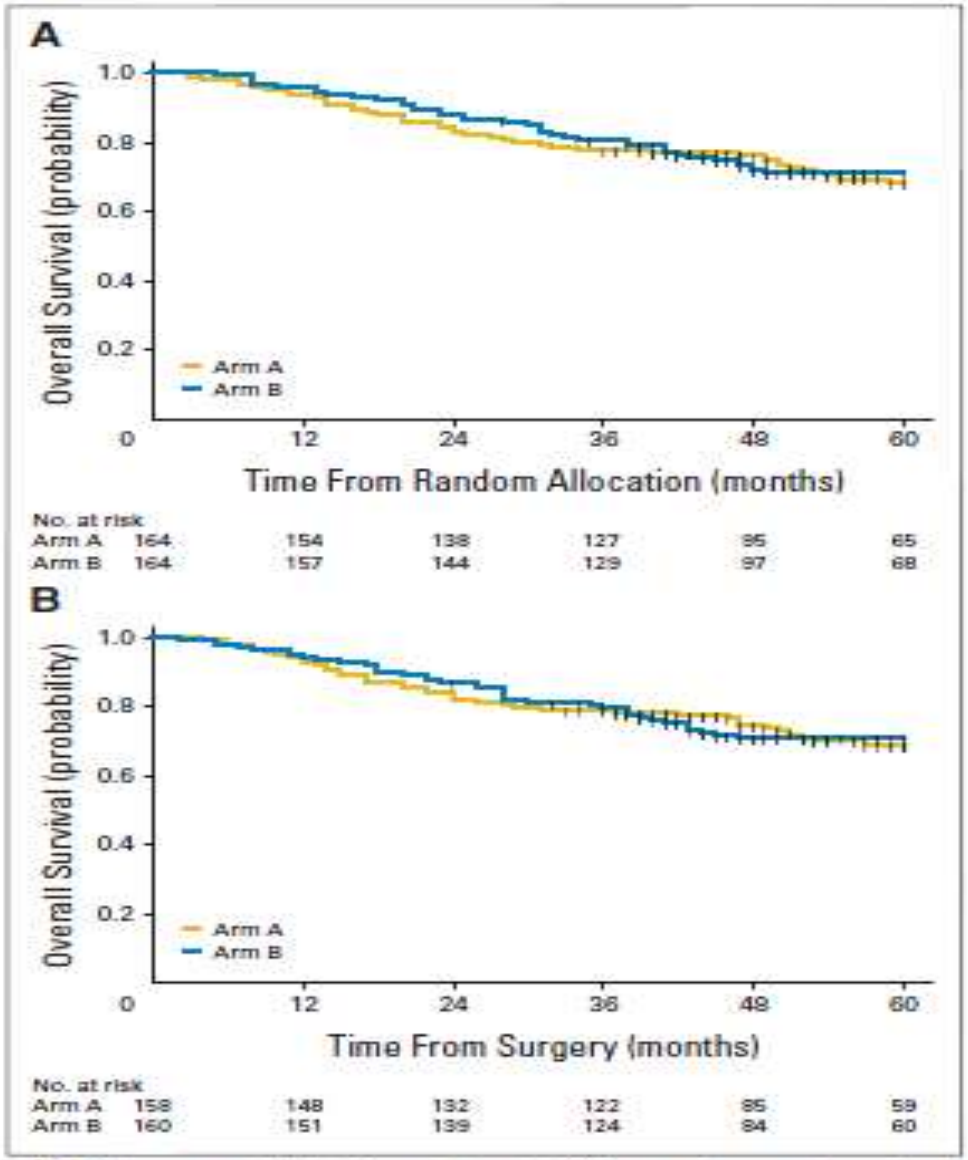

Fig 2. Five-year probability of overall survival (A) from random assignment and (B) from surgery according to study arm.

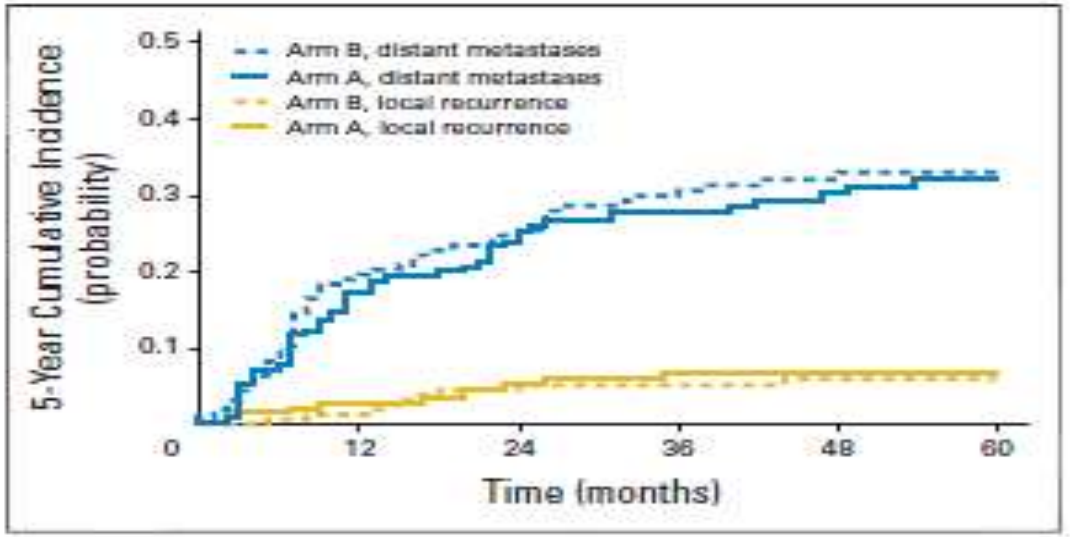

Fig 3. Five-year cumulative incidence of local recurrence and distant metastases according to study arm.

Gronchi et al. J Clin Oncol. 2012 Mar 10;30(8):850-6.

¿POR QUÉ RT PREOPERATORIA ?

<u>Tratamiento</u>:

Fuente radiación: Acelerador lineal de electrones ONCOR, energía utilizada: Fotones 6 y 15 MV

Volumen blanco (CTV): Masa del compartimento adductor del muslo derecho

Volumen planificado (PTV): CTV + margen

Planificación: Se realiza planificación mediante TAC con paciente en decúbito supino con inmovilización de extremidad inferior derecha.

Dosis por fracción: 200 cGy

Dosis total: 54 Gy

Duración del tratamiento:11/12/2013 al 23/1/2014

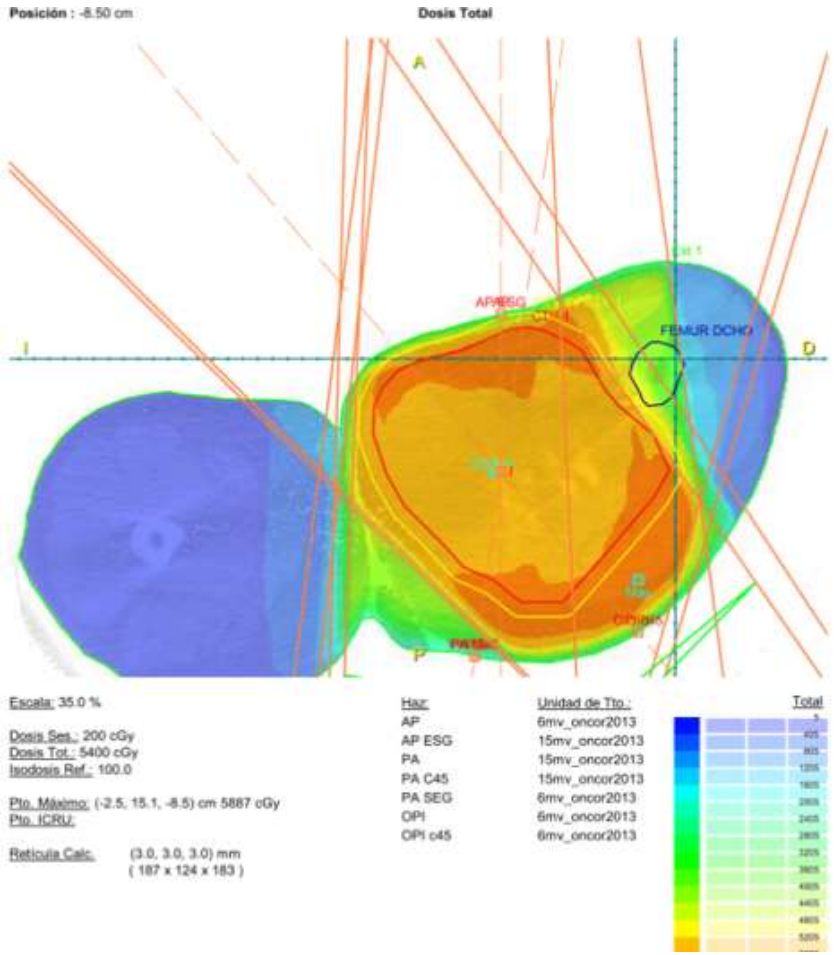

Preoperative versus postoperative radiotherapy in soft-tissue sarcoma of the limbs: a randomised trial

Brian O'Sullivan, Aileen M Davis, Robert Turcotte, Robert Bell, Charles Catton, Pierre Chabot, Jay Wunder, Rita Kandel, Karen Goddard, Anna Sadura, Joseph Pater, Benny Zee

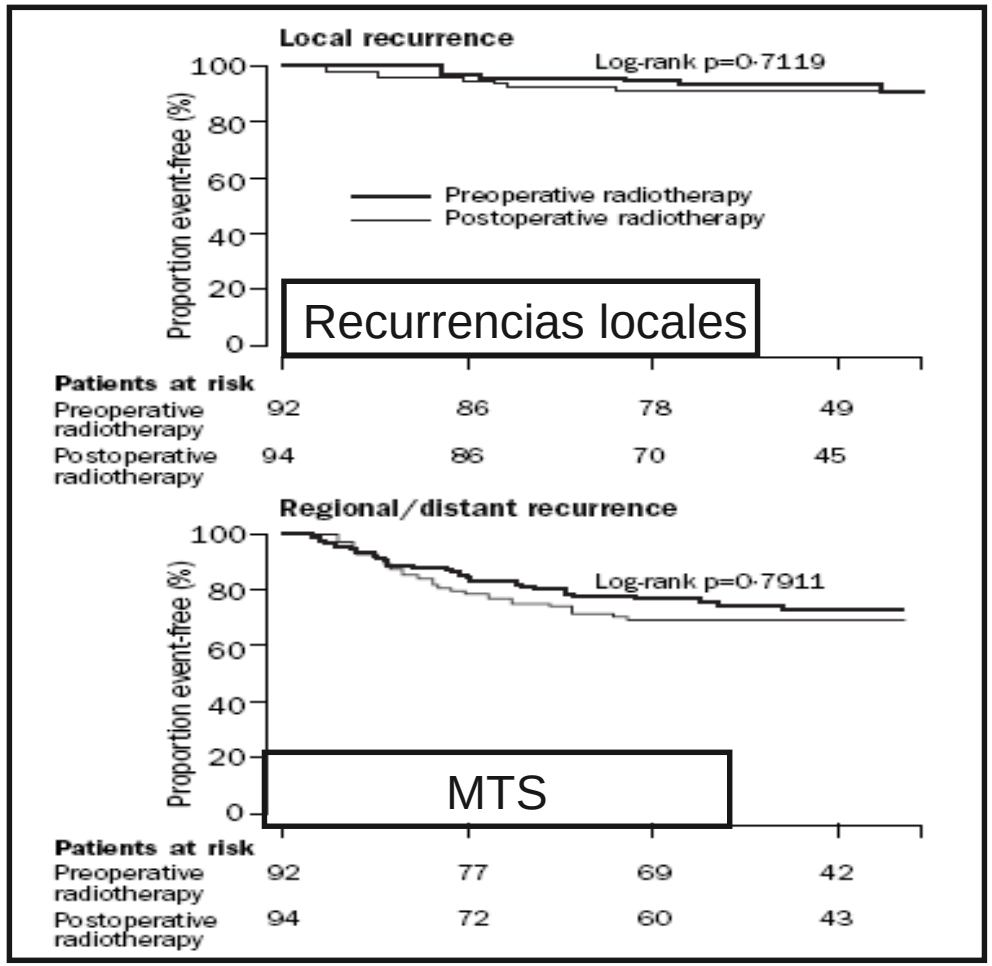

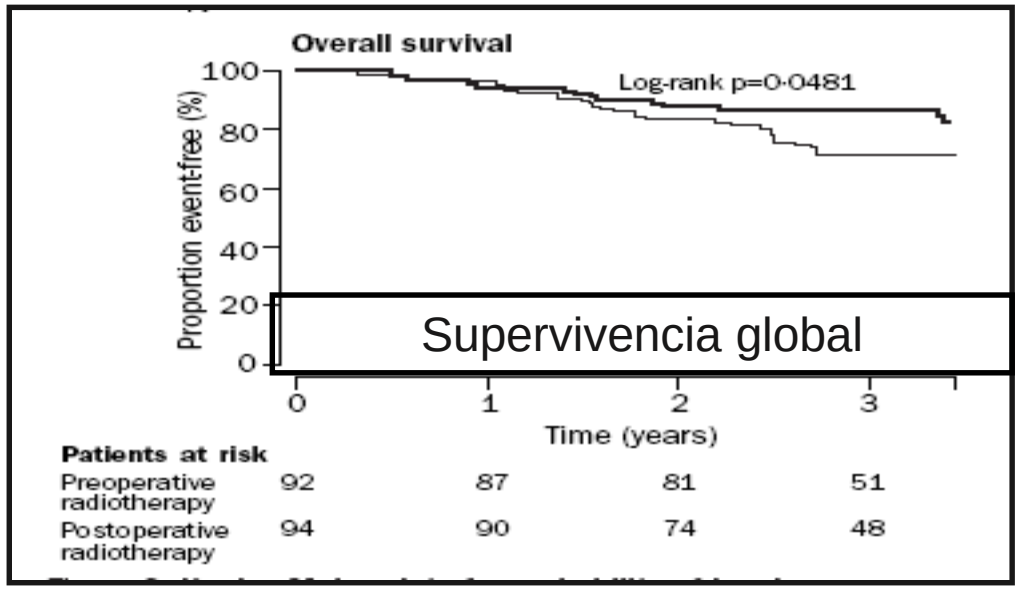

No diferencias entre ambos tratamientos en control local, metástasis o supervivencia global.

Lancet 2002; 359:2235-41.

Late radiation morbidity following randomization to preoperative versus postoperative radiotherapy in extremity soft tissue sarcoma

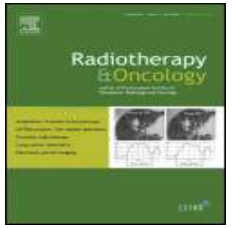

RT preoperatoria → Más infección de la herida quirúrgica

RT postoperatoria → Más complicaciones tardías

	RT preop 50 Gy	RT postop 65 Gy	
Fibrosis ≥ 2	**32%**	**48%**	*p=0.07*
Edema	**15%**	**23%**	*NS*
Rigidez articular	**18%**	**23%**	NS

Radiother Oncol 2005; 75:48-53.

1. METANALISIS
QT adyuvante con
DOXO-IFOSFAMIDA:
Beneficio en DFS y probable en OS

2. ENSAYO ITALIA-ESPAÑA
QT NEOady =
QT NEOady+ ADY

3. ESTUDIOS RT PRE /POSTOPERATORIA
RTpreop = Rtpostop
(↓Toxic. Tardía)

ES RAZONABLE UTILIZAR QT (IFO-DOXO)Y RT PREOPERATORIA EN SARCOMAS DE EXTREMIDADES:

- **IGUAL SUPERVIVENCIA**
- **MEJORA POSIBILIDADES DE CIRUGÍA CONSERVADORA**
- **DISMINUYE TOXICIDAD**
- **ESPECIALMENTE EN ALGUNOS SUBTIPOS: SARCOMA NOS, SPI.**

TRATAMIENTO QT

- 8/11/13- 21/12/13 : 3 ciclos de QT Neadyuvante con Ifosfamida-Epirrubicina.
  - Epirubicin 60 mg/m2/dia dias 1y 2.
  - Ifosfamida 3 g/m2 /dia dias 1,2, y 3 cada 21 dias .

ENSAYO CLINICO **ISG-STS 10-01/GEIS25**

ISG-STS 10-01/GEIS25: Multicéntrico fase III randomizado

Sarcomas de partes blandas localizados de alto riesgo de extremidades y pared de tronco en adultos: un enfoque integrador que incluye quimioterapia estándar vs histotipo-dirigida neoadyuvante

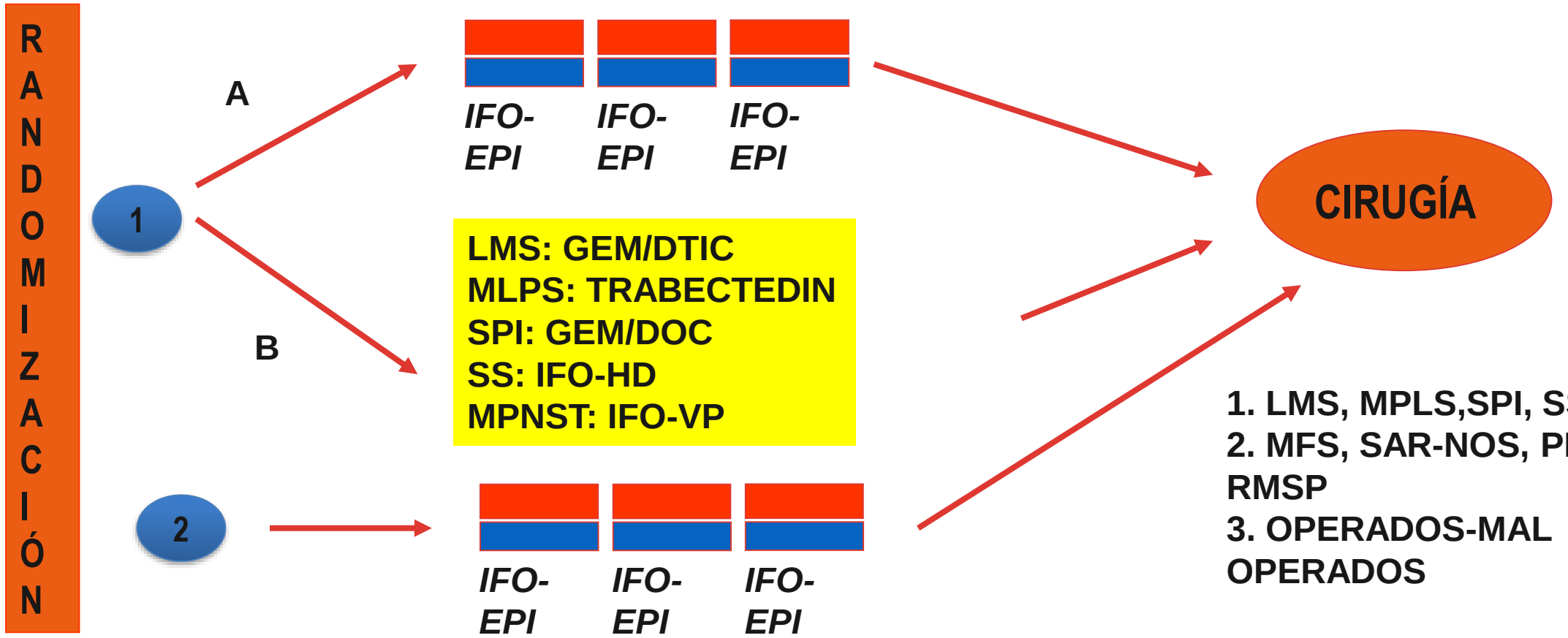

Gronchi et al. Lancet Oncol.2017 May 9.

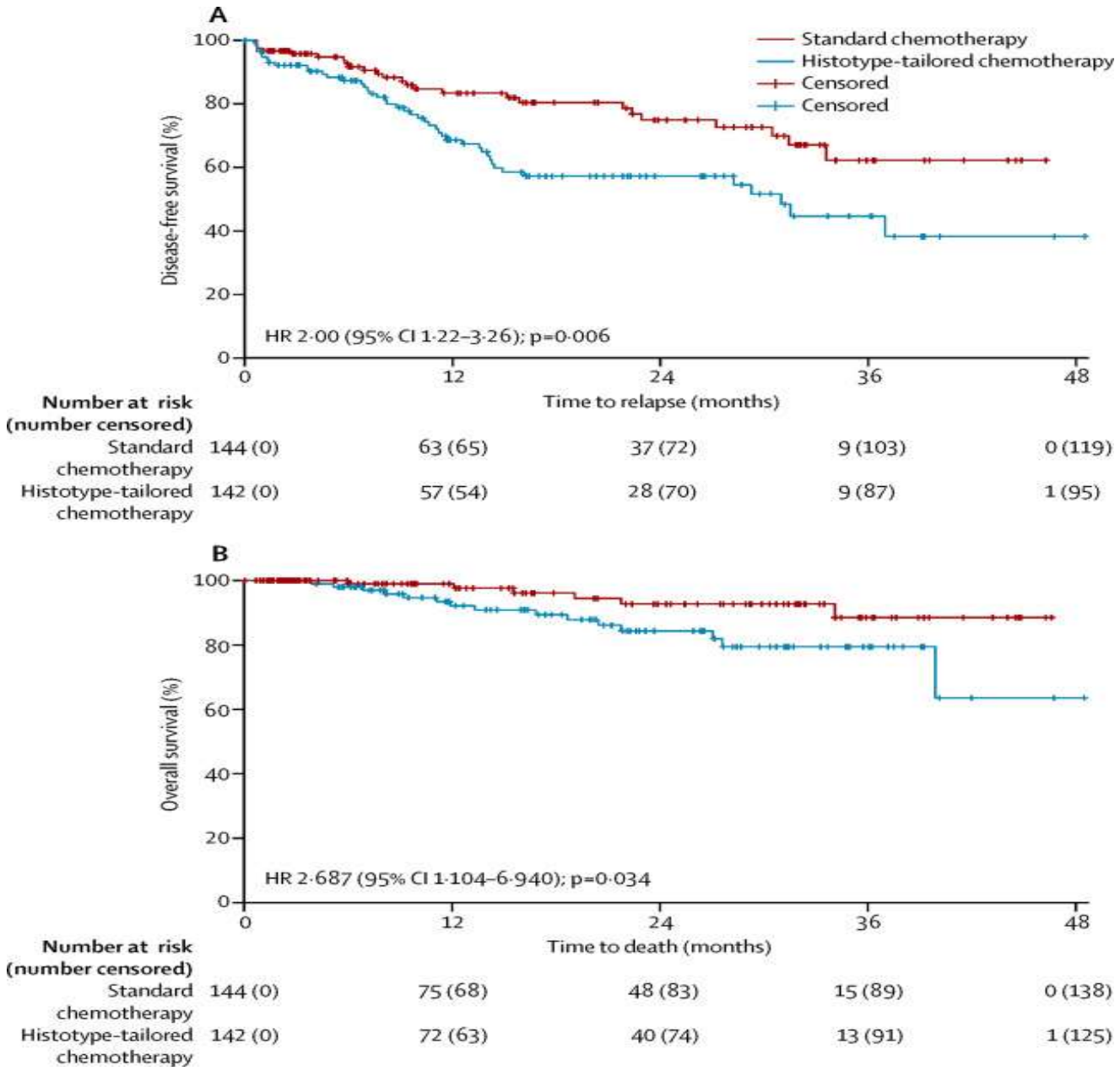

Gronchi et al. Lancet Oncol.2017 May 9.

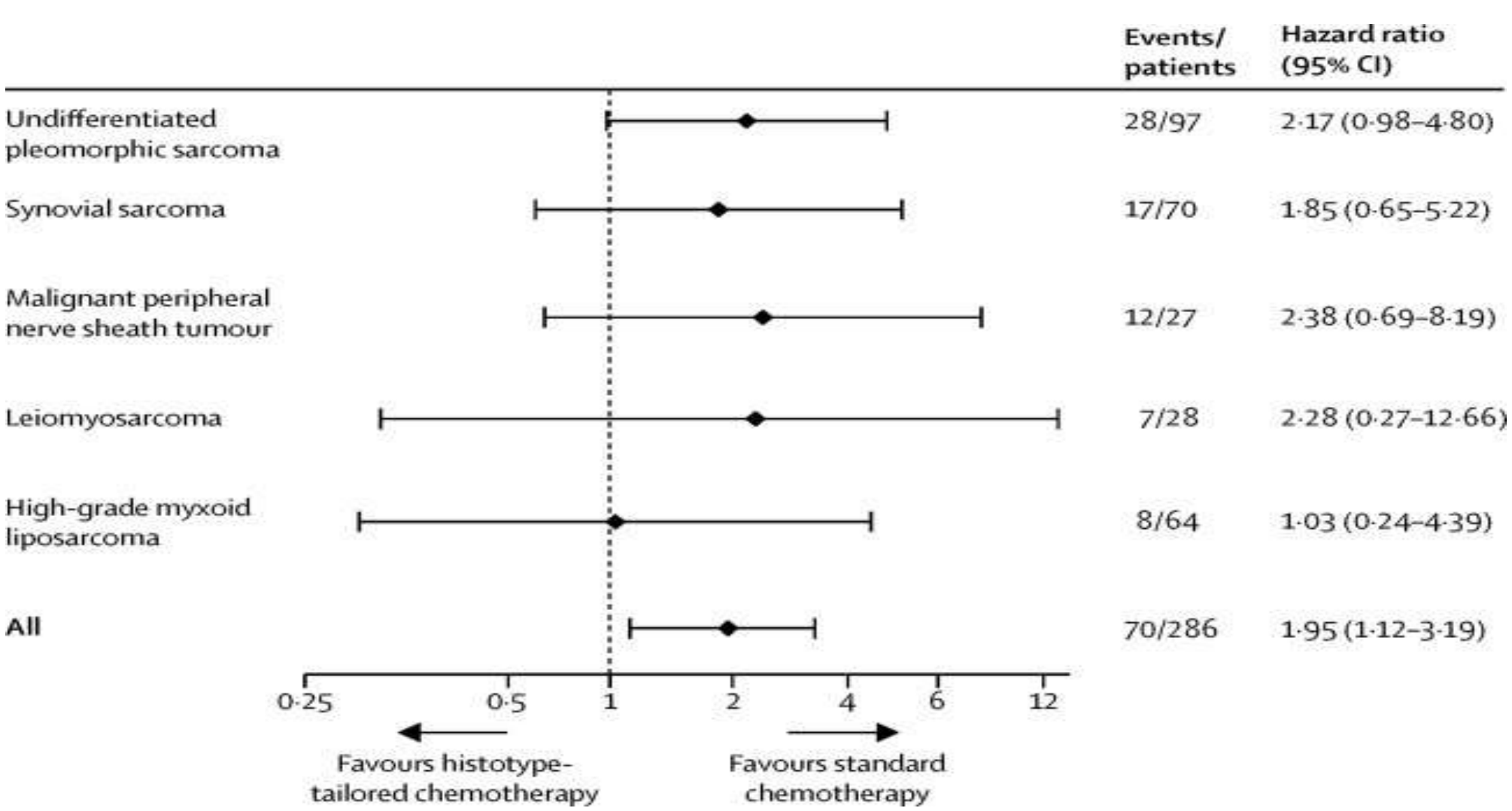

Gronchi et al. Lancet Oncol.2017 May 9.

6. EVALUACIÓN DE RESPUESTA RADIOLÓGICA

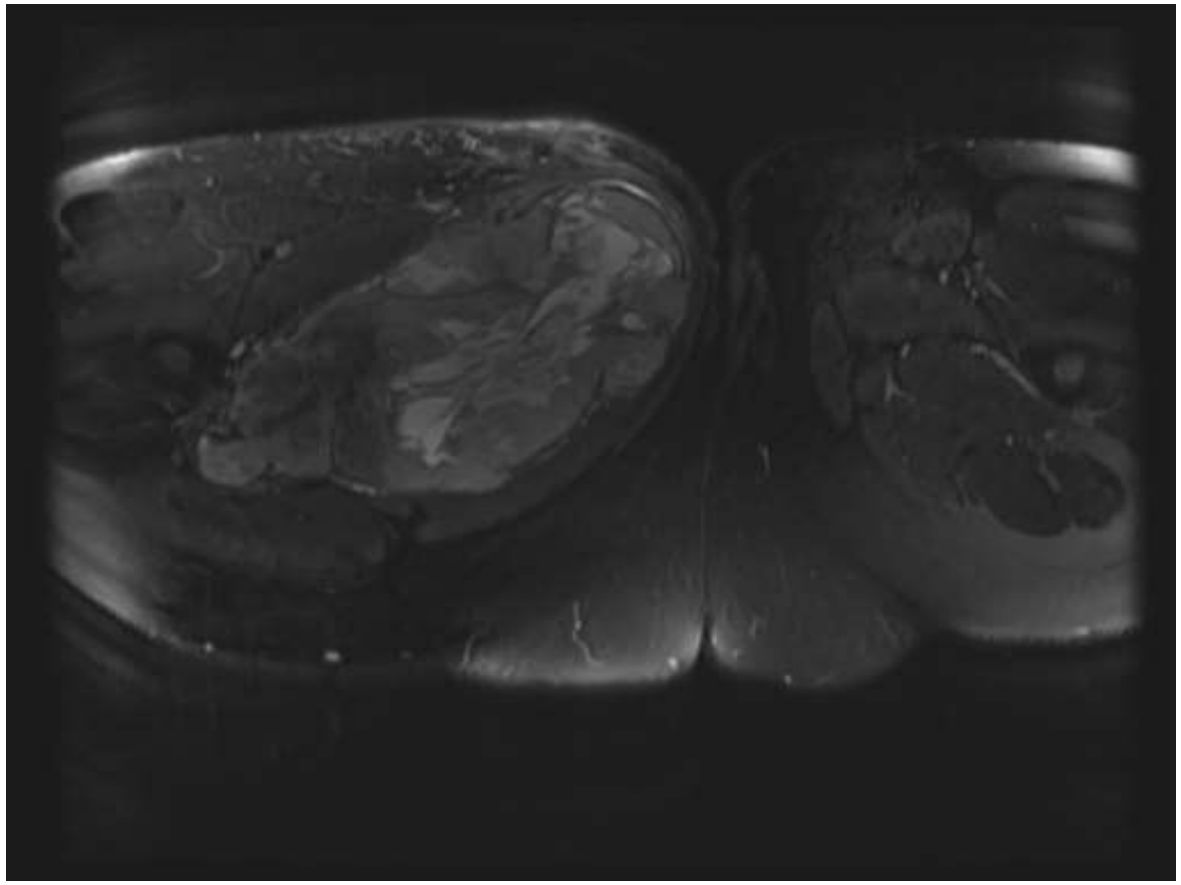

6/11/2013
ANTES DE TRATAMIENTO

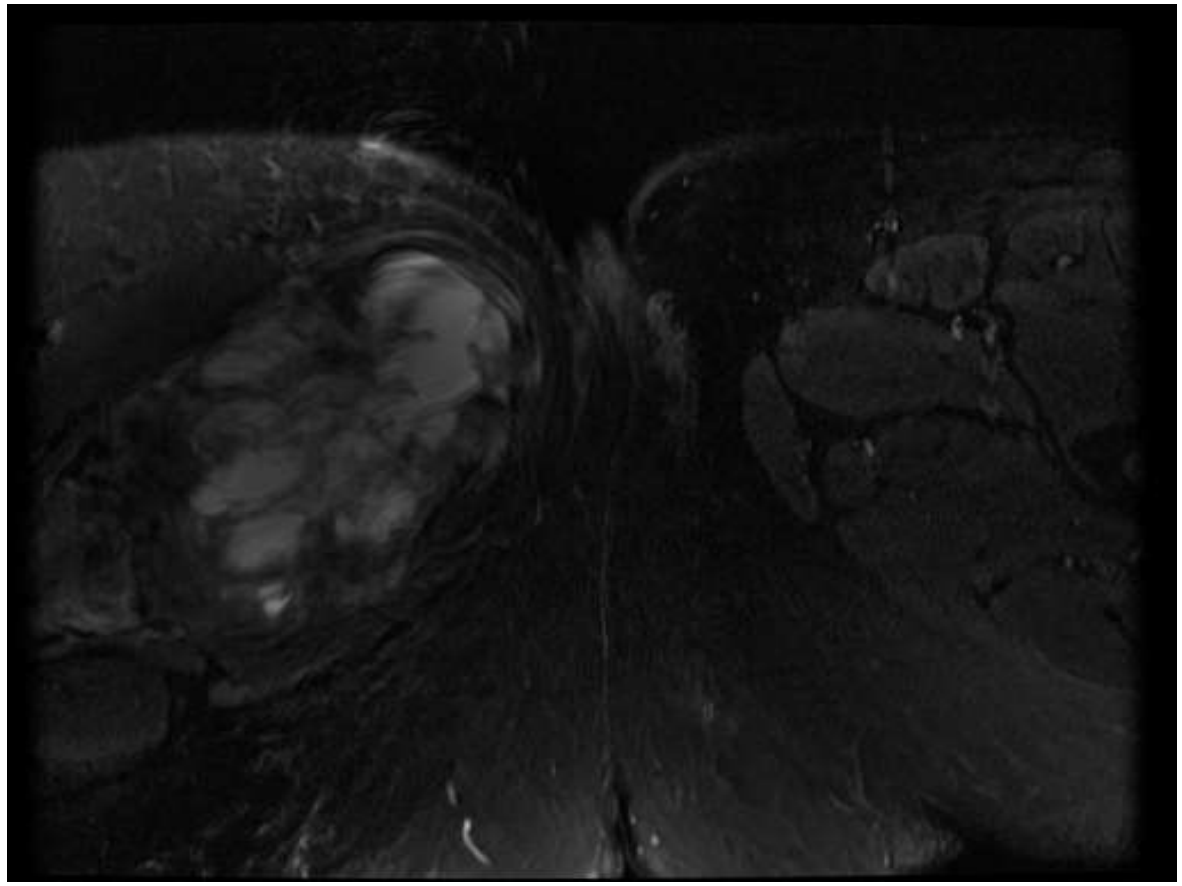

6/2/2014
TRAS TRATAMIENTO QT Y RT

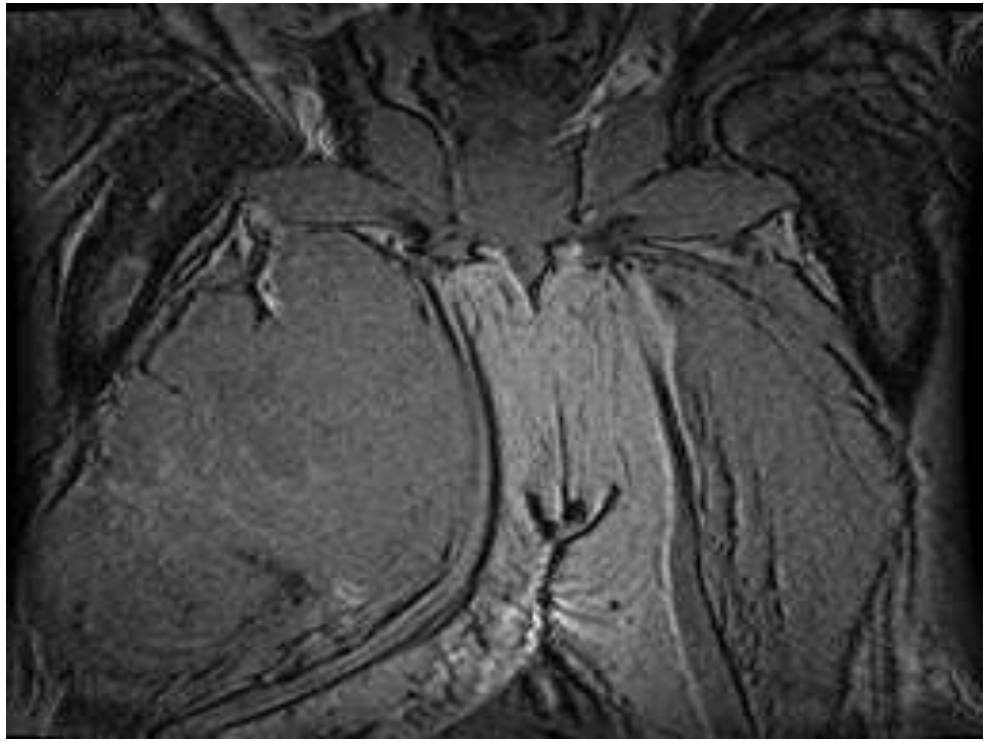

6/11/2013
ANTES DE TRATAMIENTO

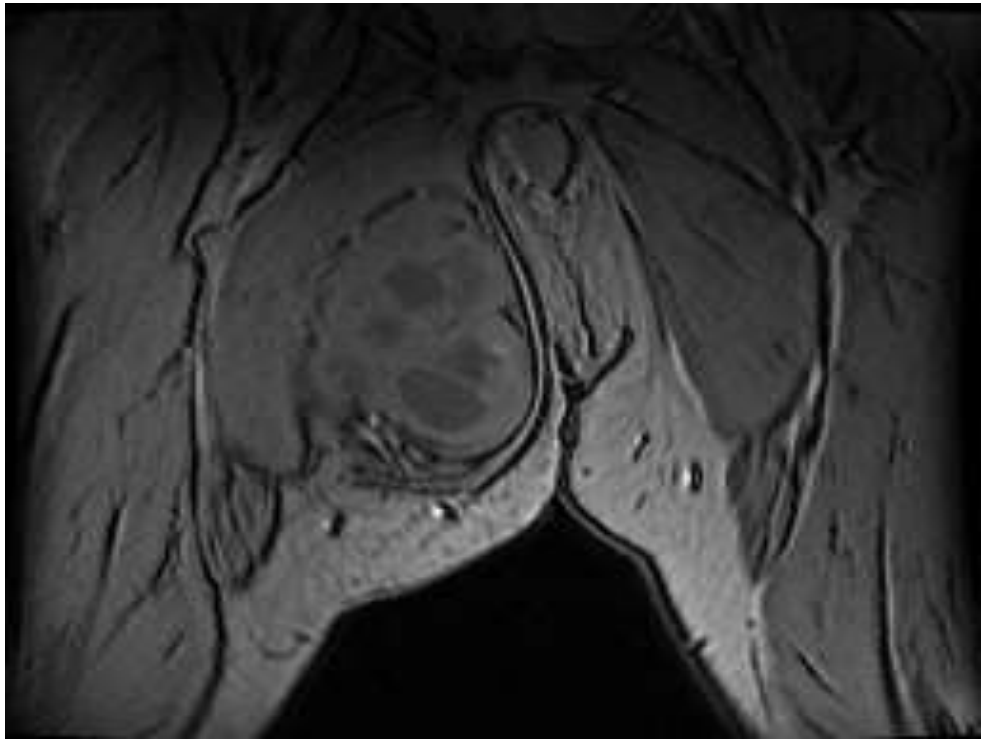

6/2/2014
TRAS TRATAMIENTO QT Y RT

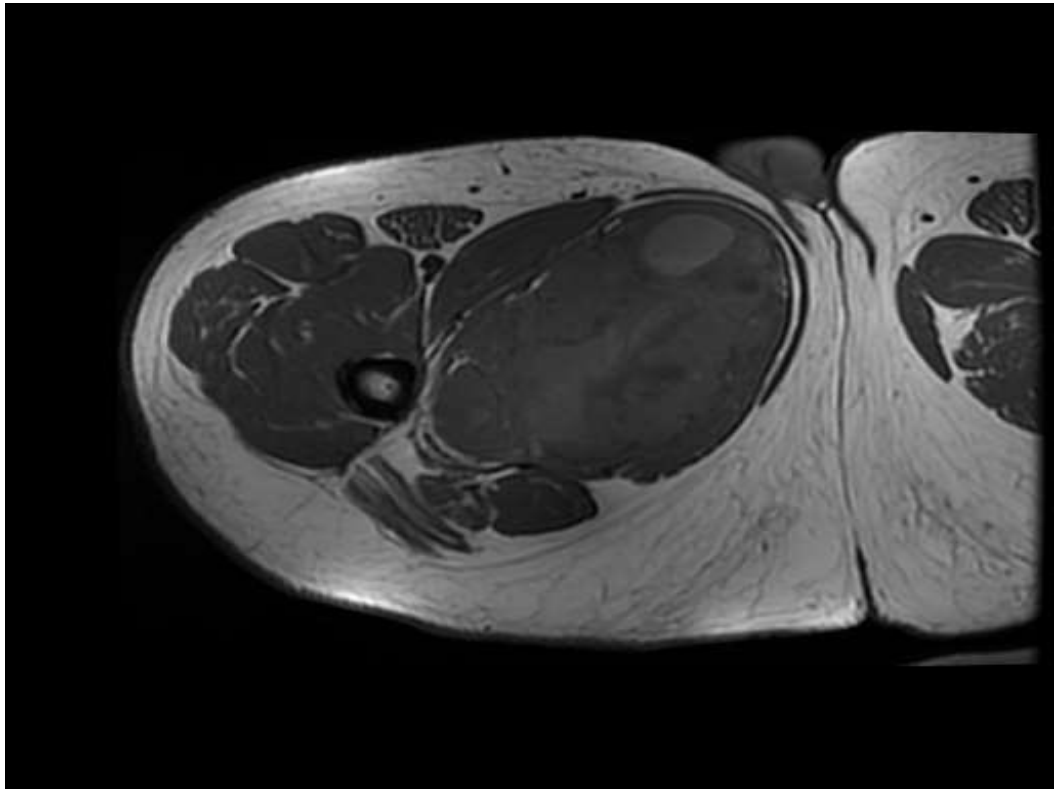

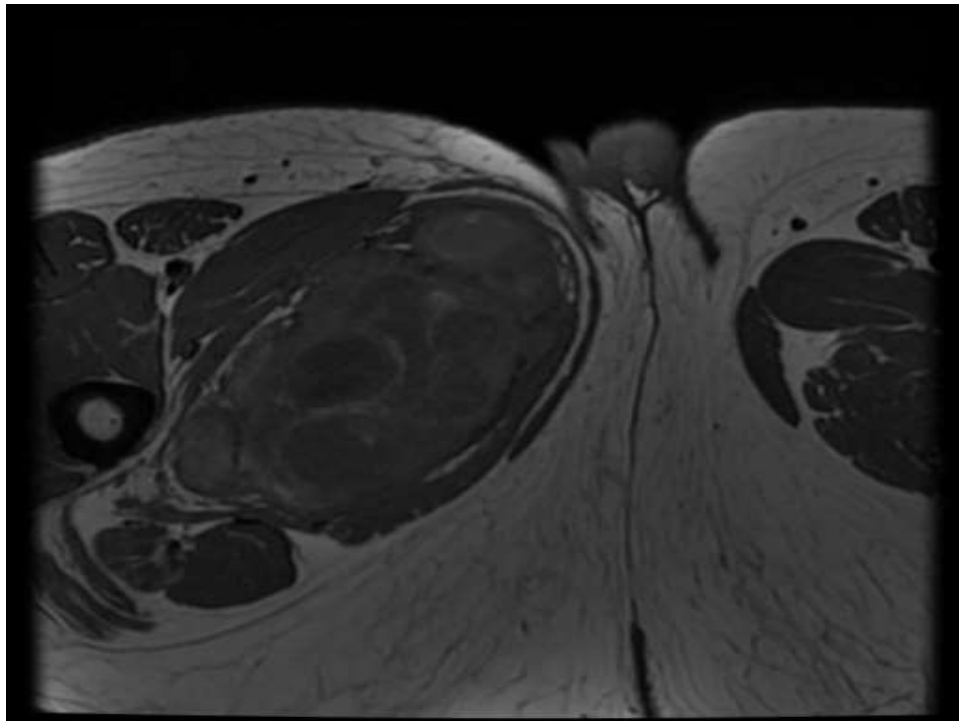

6/11/2013
ANTES DE TRATAMIENTO

6/2/2014
TRAS TRATAMIENTO QT Y RT

B. Valoración rta. QT neoadyuvante

- Estudio de extensión mediante TC TA negstivo **(enfermedad localizada)->** Ingresa en Octubre para inicio QT **neoadyuvante (Sa alto grado):** Ifosfamida+Epirrubicina dentro de EC GEIS-25.
- **Se sigue protocolo**, con **RM tras 1er ciclo y previo a cirugía**

- **RM 5 Dic de 2013, tras 1 ciclo QT. Sin cambios**

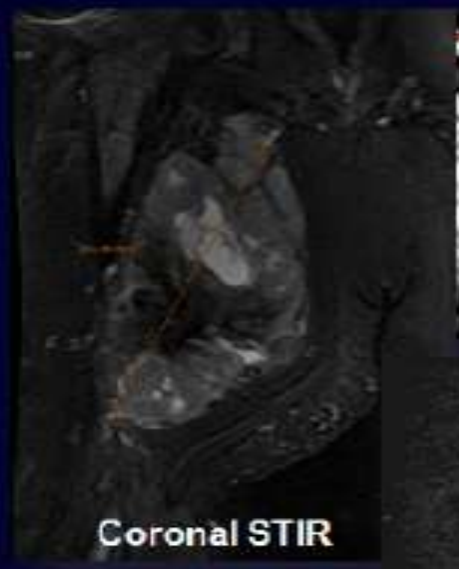

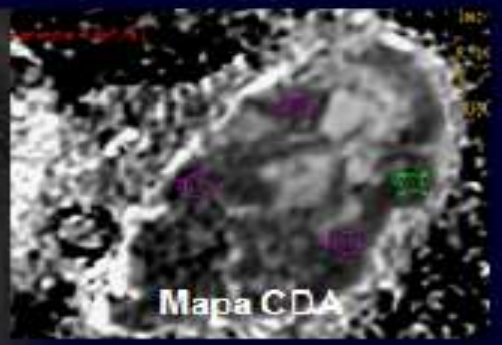

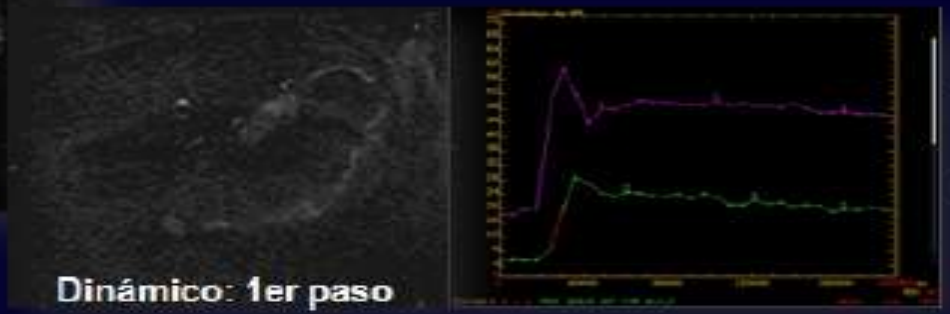

- **RM morfológica: Mismo tamaño (22cm) y patrón morfológico**
- **RMD: No cambios aparentes en estudio dinámico**
- **dWI: similar**

-CDAmin (sonas sólidas): 0,98 (↑0,13: 15%)

-CDAmedio: 1,58 (↑0,5: 0,3%)

B. Valoración rta. QT neoadyuvante

- RM 6 Feb 2014.tras finalizar QT neoadyuvante y antes cirugia

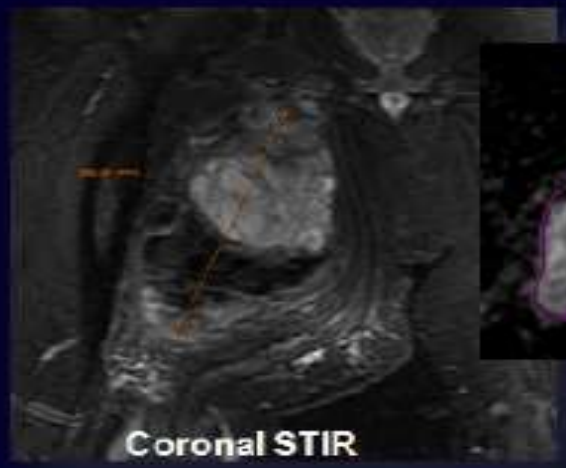

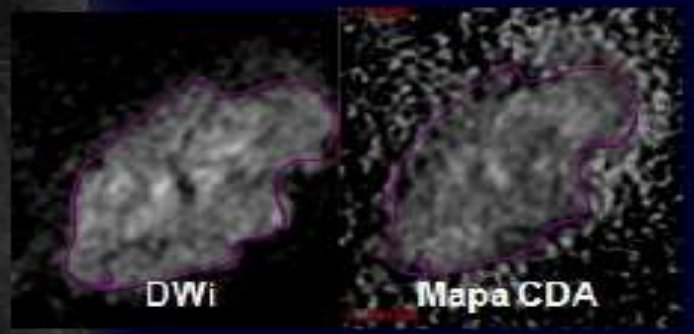

- RM morf:
- ↓tamaño 21% reducción DM, pero EE (EE RECIST)
- Cuantificación realce (crit. Choi modif.): ↓30% (RP) * (RP CHOI-RM)
- dWI: ↑CDA medio a 2,5 y CDAmin (focal) a 2,44 *
- RMD: persisten focos sospechosos tm viable en imagen 1er paso (realce precoz), curva 3 con - pendiente. *Slope* ↓ de 1305 a 588%/m (↓55%) *

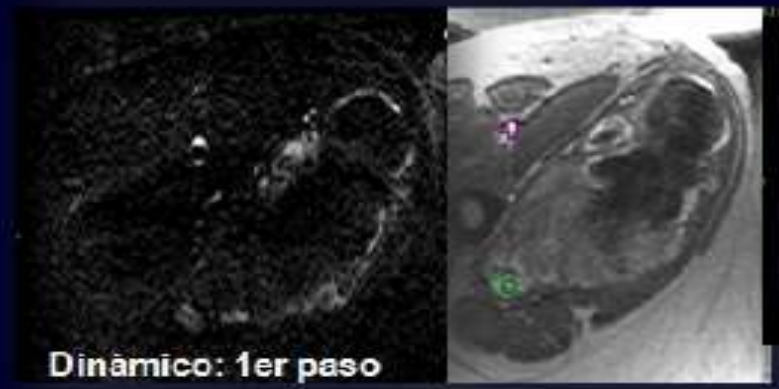

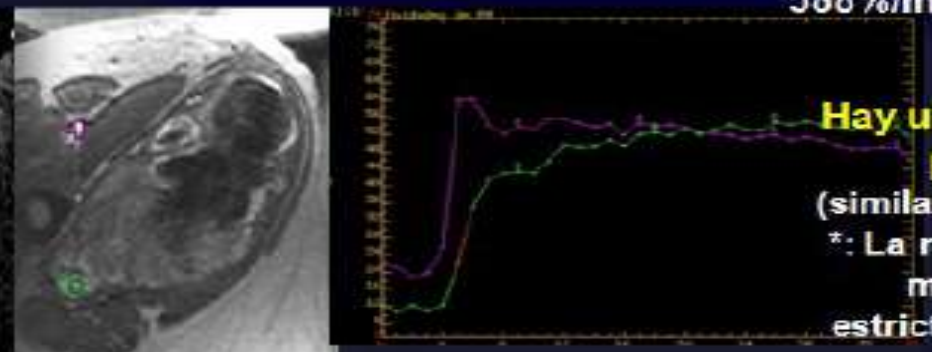

Hay una cierta rta. al tto. aunque probablemente pobre
(similar a la RP: rta. parcial discreta)
*: La realización de estudio en otra máquina impide comparar estrictamente valores cuanrtativos

7.TRATAMIENTO QUIRÚRGICO

Planificación:
Tipo de resección

Resección AMPLIA del aductor mayor y menor

La agresividad de la tumoración exigiría una resección RADICAL que sería equivalente a una desarticulacion de cadera funcional.

Resección MARGINAL insuficiente para el control local de la enfermedad

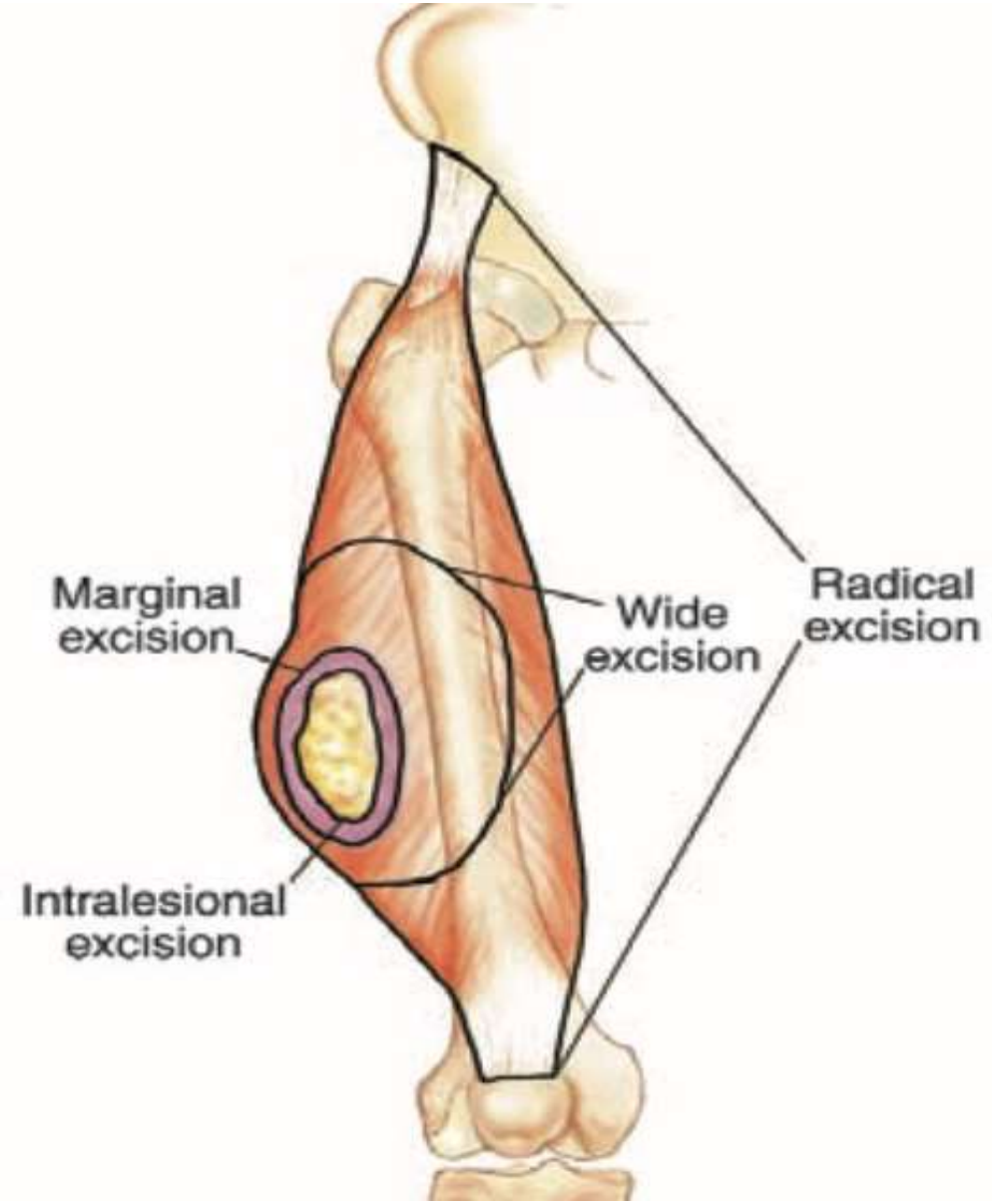

Planificación

Ligadura de arterias provenientes de la femoral profunda y arteria obturatriz.

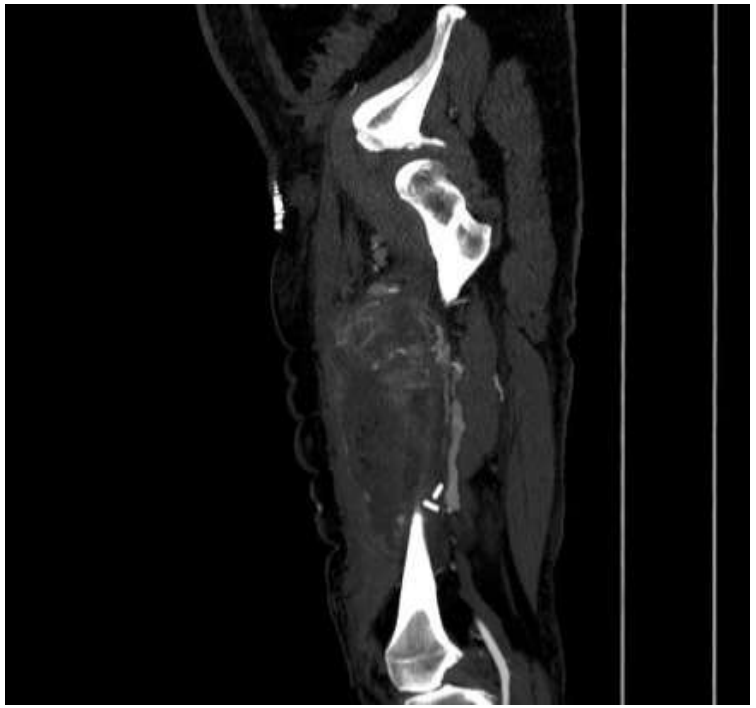

Cirugía: Resección amplia

Intervención el 13-2-14

Resección circunferencial tumoral con límites amplios.

Incluye adductor mayor y menor

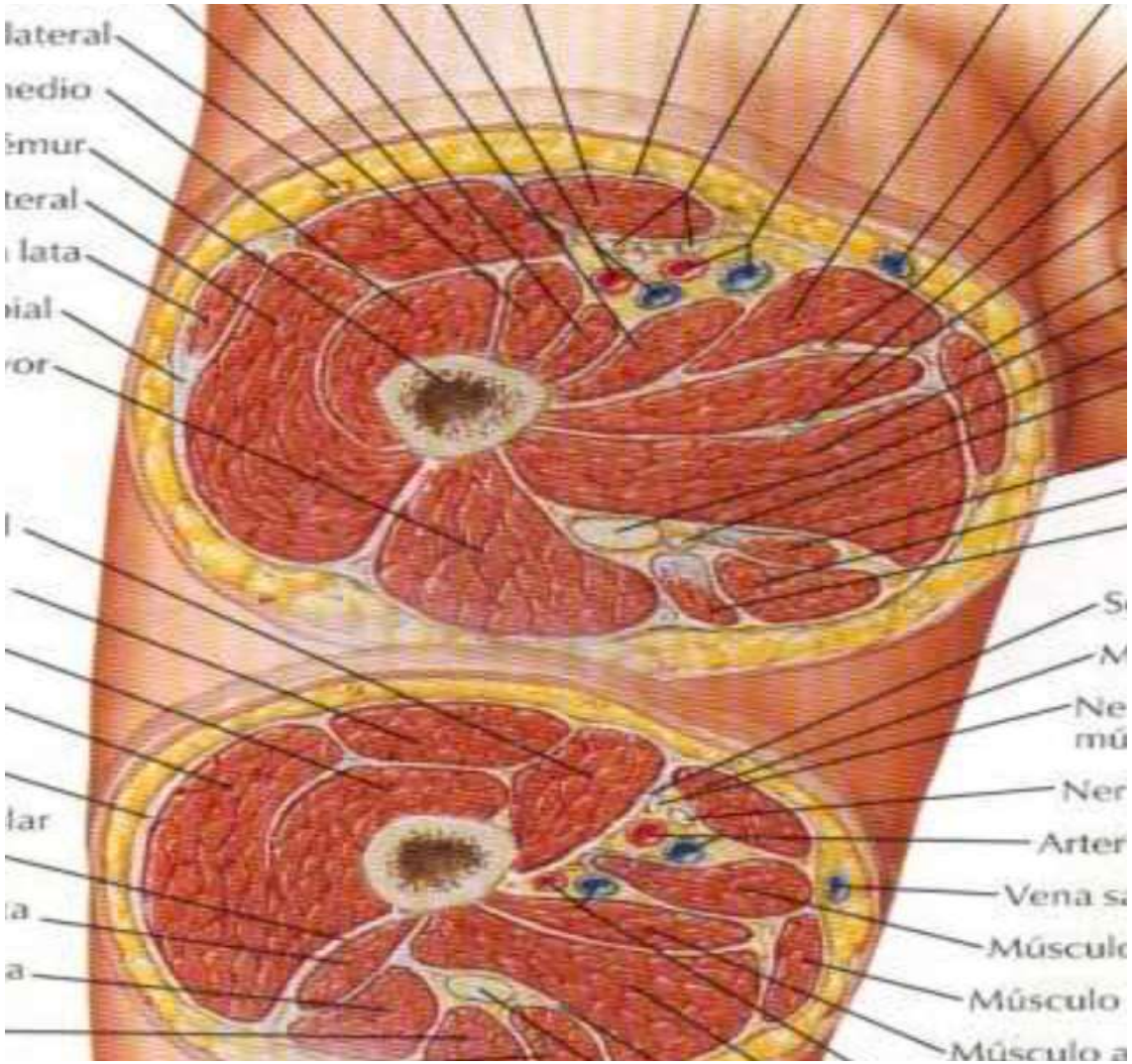

Planificación

Sin actuación reconstructiva del defecto. Mantiene potencia aductora con aductor largo e isquiotibiales

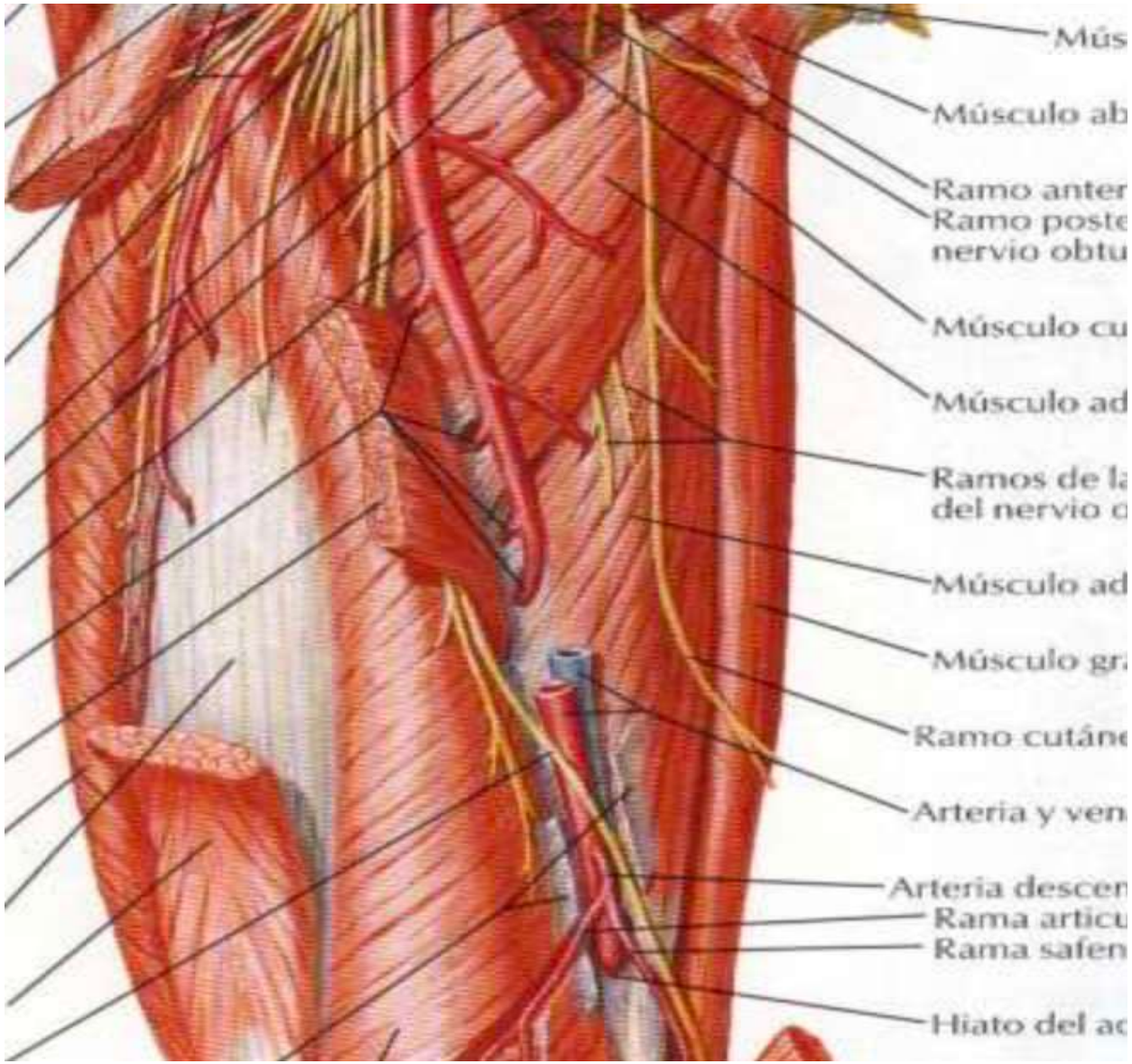

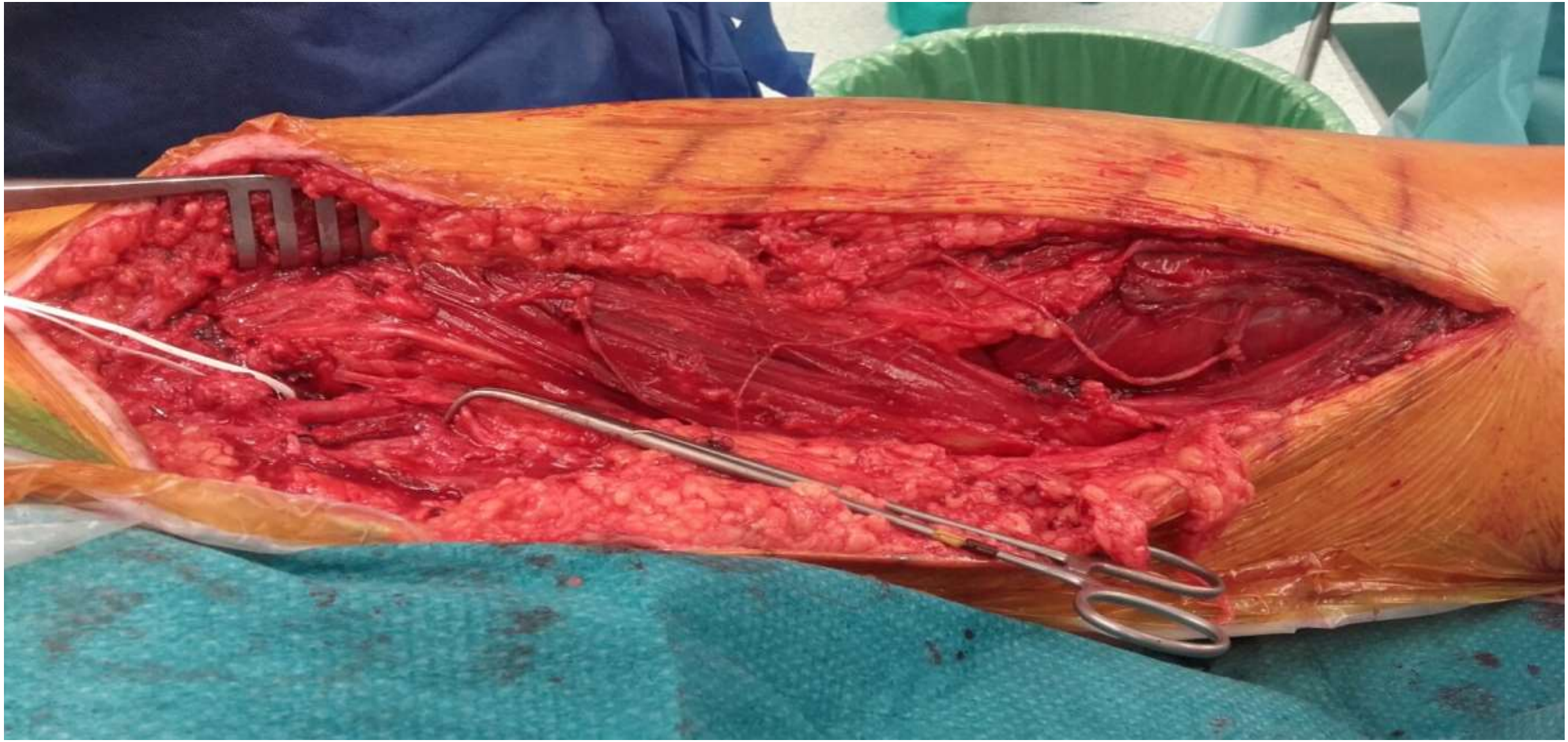

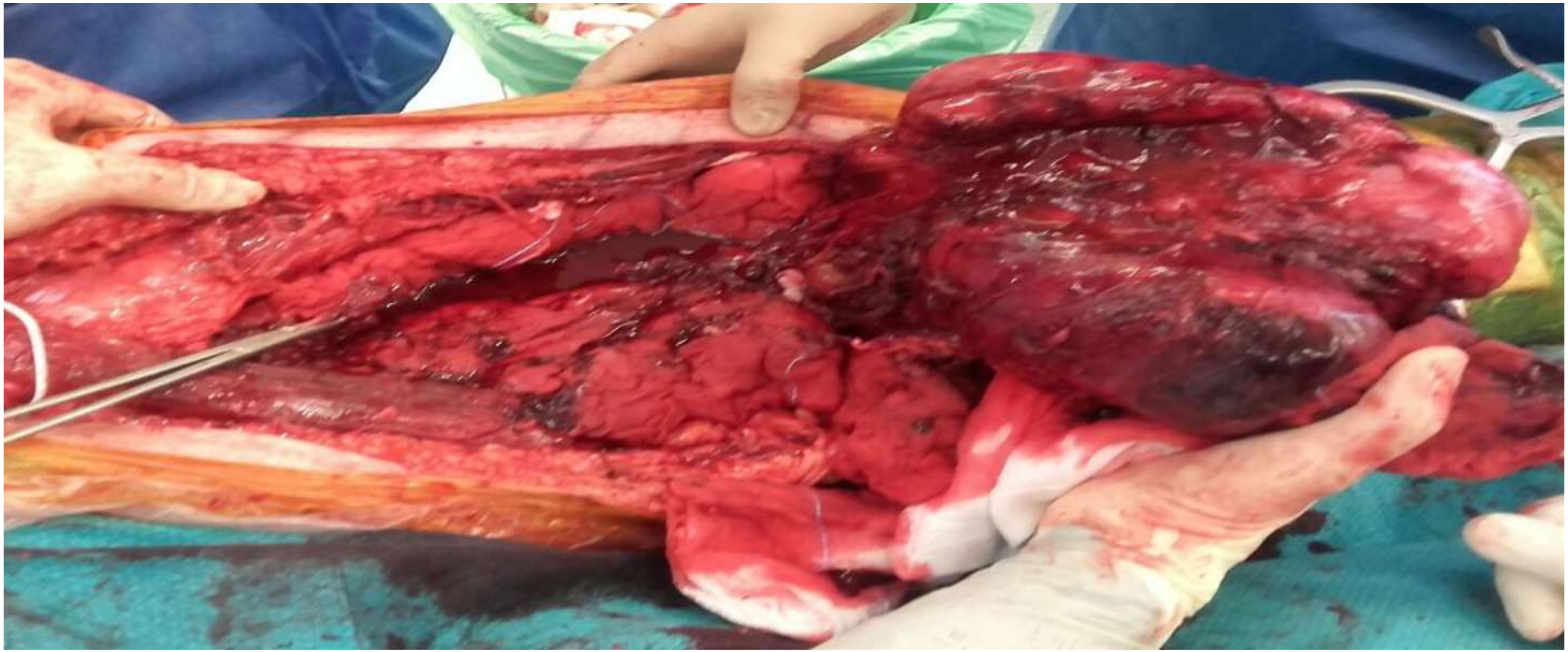

Postoperatorio

Postoperatorio hospitalario

Sin complicaciones

Alta hospitalaria a los 10 días de la cirugía.

Seguimiento en consulta

Descarga total ……. 2 semanas

Apoyo parcial con 2 muletas…… 2 semanas

Apoyo parcial con 1 muleta ……2 semanas.

Valoración a 6 meses

Sin dolor

Arco de movilidad de rodilla y cadera completa

Pérdida de fuerza aductora del 40%

8. EVALUACION DE RESPUESTA PATOLÓGICA

Macroscopic and microscopic pathological examination

- Analysis of the post-treatment specimens for the assessment of:

- Quality of margins
- **Pathologic response**
  - % tumor necrosis
  - % residual viable tumor cells & distribution
  - other components

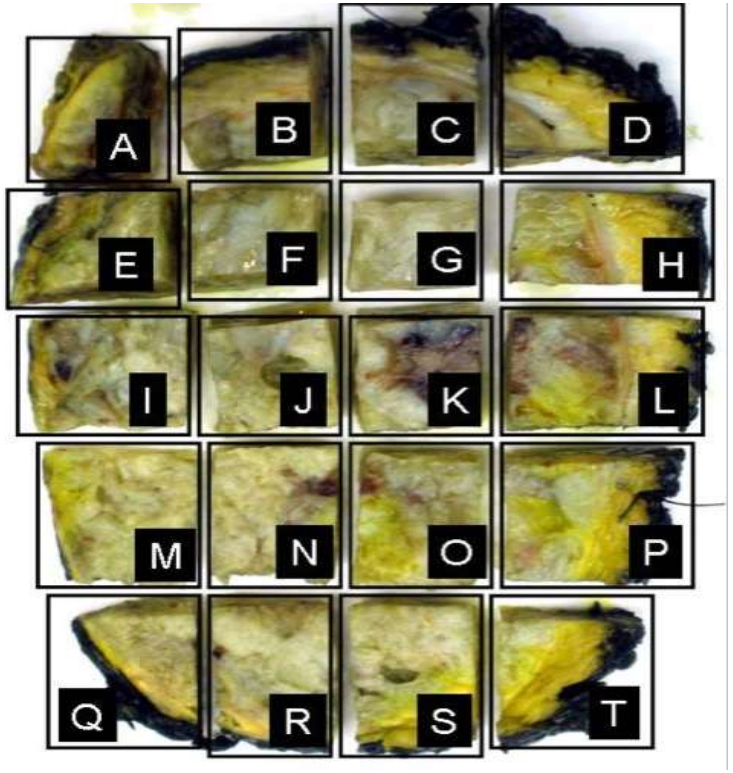

Effects of neoadjuvant therapy (histological response)

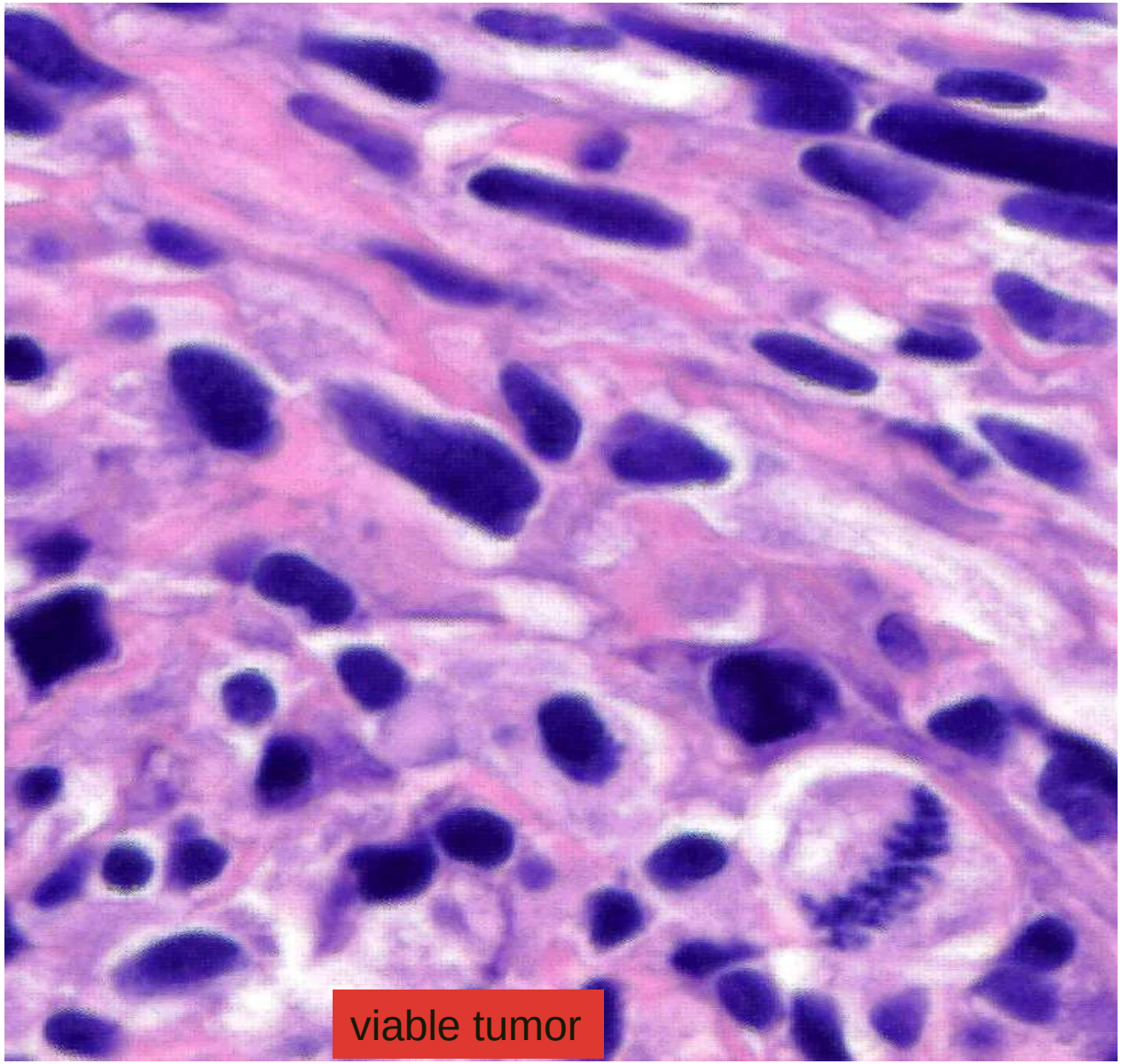

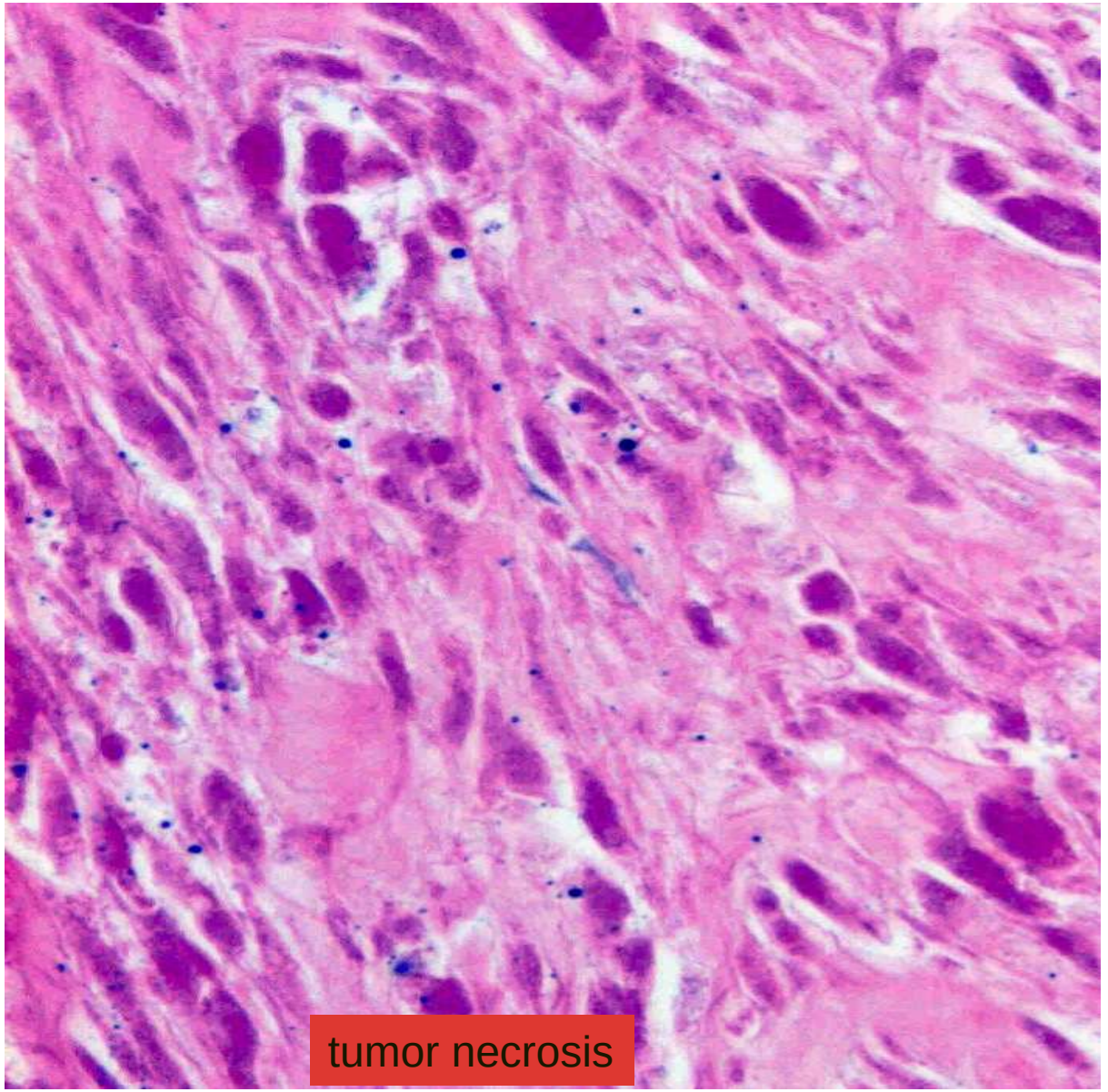

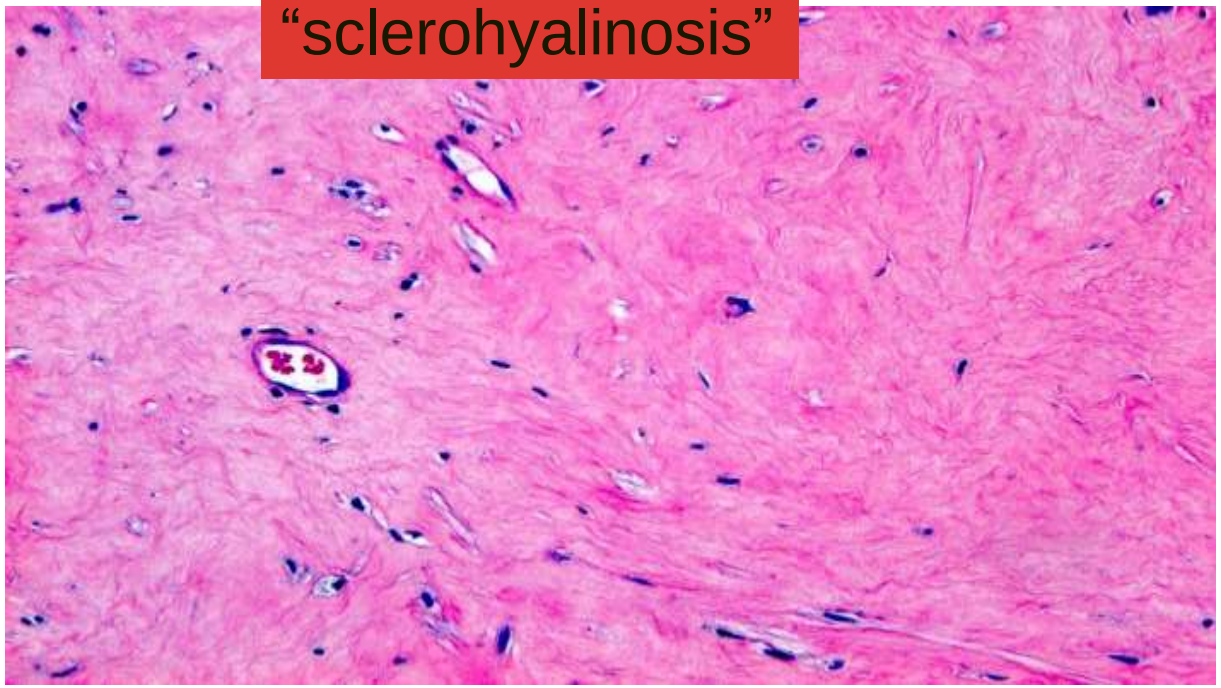
“sclerohyalinosis”

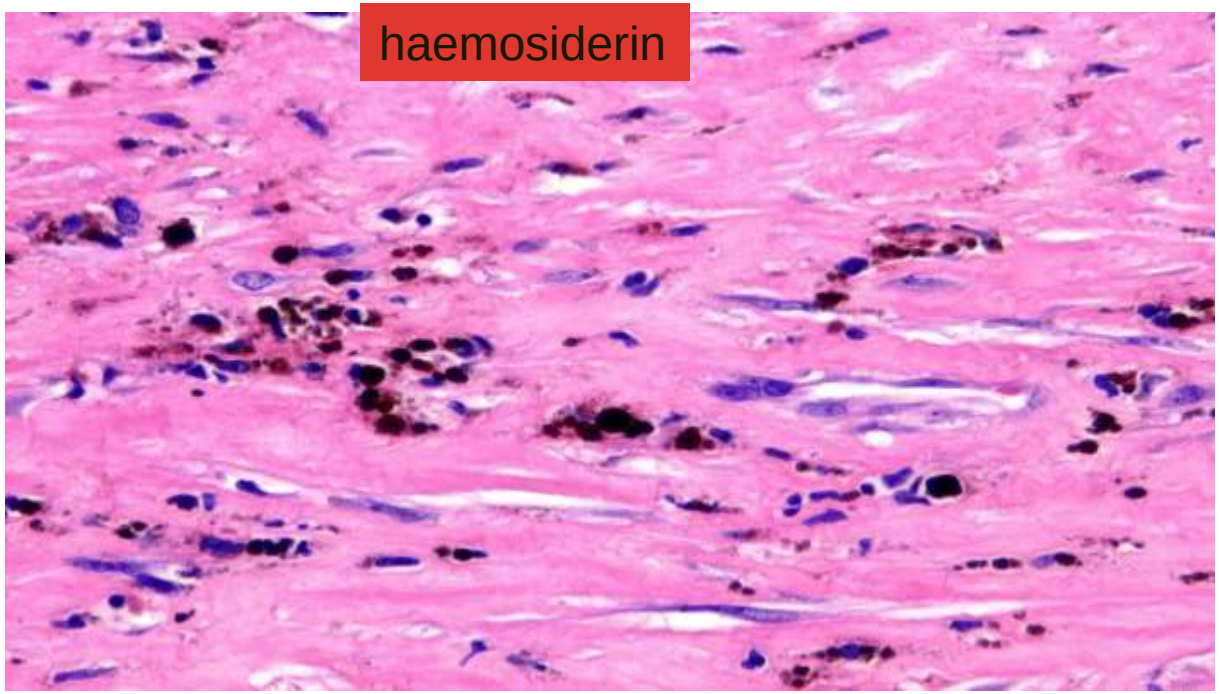
haemosiderin

“colesterol clefts”

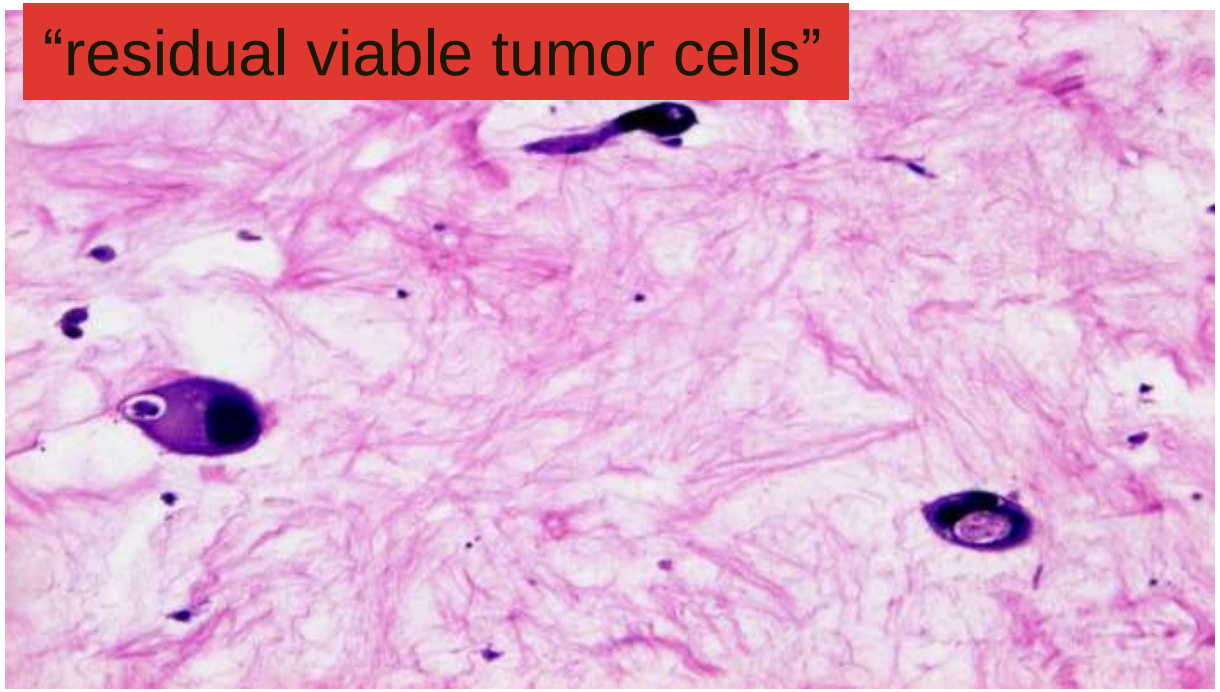
“residual viable tumor cells”

Evaluation of response after neoadjuvant treatment in soft tissue sarcomas; the European Organization for Research and Treatment of Cancer—Soft Tissue and Bone Sarcoma Group (EORTC—STBSG) recommendations for pathological examination and reporting

- % Células teñidas

- % Necrosis
- Fibrosis/esclerohialinosis
- Macrófagos
- Hemorrágia.....

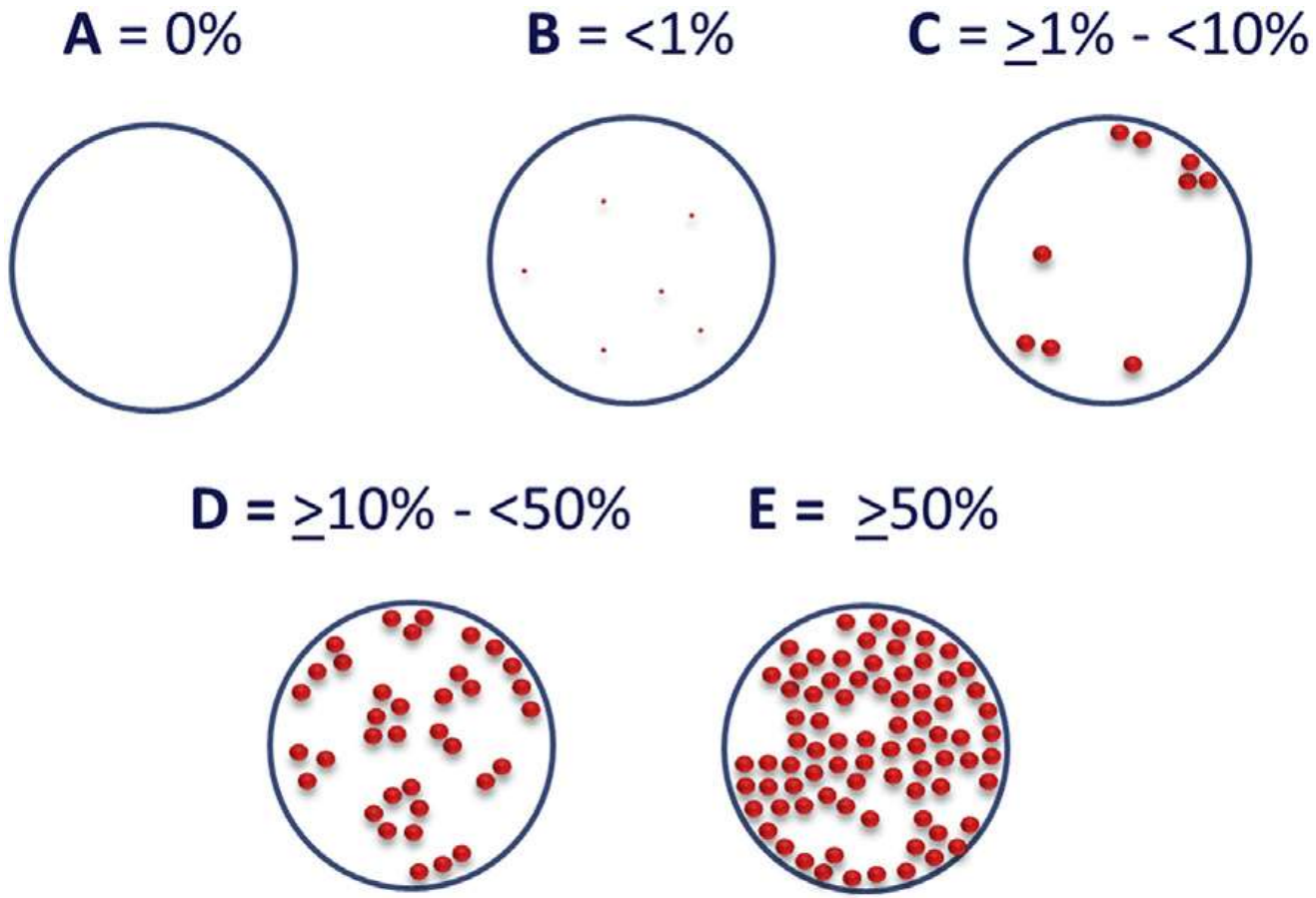

Wardelmann et all
European Journal of Cancer 53(2016) 84-95

	N	5-year RFS	*P* value	5-year OS	*P* value
Tumor Size					
<5 cm	24	86%	0.02	91%	0.08
≥5 cm	76	63%		71%	
Histologic Subtype					
Unclassified	34	68%	0.01	74%	<0.0001
Myxofibrosarcoma	25	76%		86%	
Leiomyosarcoma	8	63%		60%	
Myxoid Liposarcoma (LPS)	6	50%		100%	
Pleomorphic LPS	6	--		--	
Dedifferentiated LPS	5	--		--	
Other	16	71%		79%	
Grade					
Low	8	100%	0.005	100%	0.09
Intermediate	21	88%		86%	
High	71	59%		69%	
% Residual Viable Tumor					
0%	9	75%	0.31	100%	0.08
1-100%	91	69%		72%	
% Residual Viable Tumor					
<5%	12	82%	0.29	100%	0.13
≥5%	88	68%		70%	

MANUSCRIPT

Scheafer et al
Int J Radiat Oncol Biol Phys, 2017 Jun 1;98(2):375-383

EORTC-STGSB Response Score [1] (% Residual Viable Tumor)					
0%	9	75%		100%	
<1%	0	--	0.58	--	0.18
≥1% - <10%	9	78%		78%	
≥10% - <50%	44	68%		68%	
≥50%	38	69%		74%	
Necrosis					
0%	73	78%	0.0006	83%	0.003
2-90%	27	39%		46%	
Necrosis					
0%	73	78%		83%	
1st Quartile (2-10)	4	50%	0.007	50%	0.04
2nd Quartile (10-20)	4	--		75%	
3rd Quartile (20-50)	12	33%		39%	
4th Quartile 4 (50-90)	7	--		--	
Hyalinization/Fibrosis					
0%	22	48%	0.08	54%	0.03
5-100%	78	73%		81%	
Hyalinization/Fibrosis					
0%	22	48%		54%	
1st Quartile (5-10)	7	57%	0.04	64%	0.05
2nd Quartile (10-22.5)	32	57%		71%	
3rd Quartile (22.5-55)	19	84%		83%	
4th Quartile (55-100)	20	92%		100%	
Infarction					
0%	36	80%	0.01	87%	0.02
5-95%	64	62%		68%	

ACCEPTED

Scheafer et al
Int J Radiat Oncol Biol Phys, 2017 Jun 1;98(2):375-383

- **Cirugía post tratamiento (QT-RT)**
  - **Pieza tumor región crural derecha**
    - **1605 gr**
    - **22x17x9 cms**
    - **Pseudoencapsulada**
    - **Sólido-quística**
    - **Diámetro mayor: 17 cm**

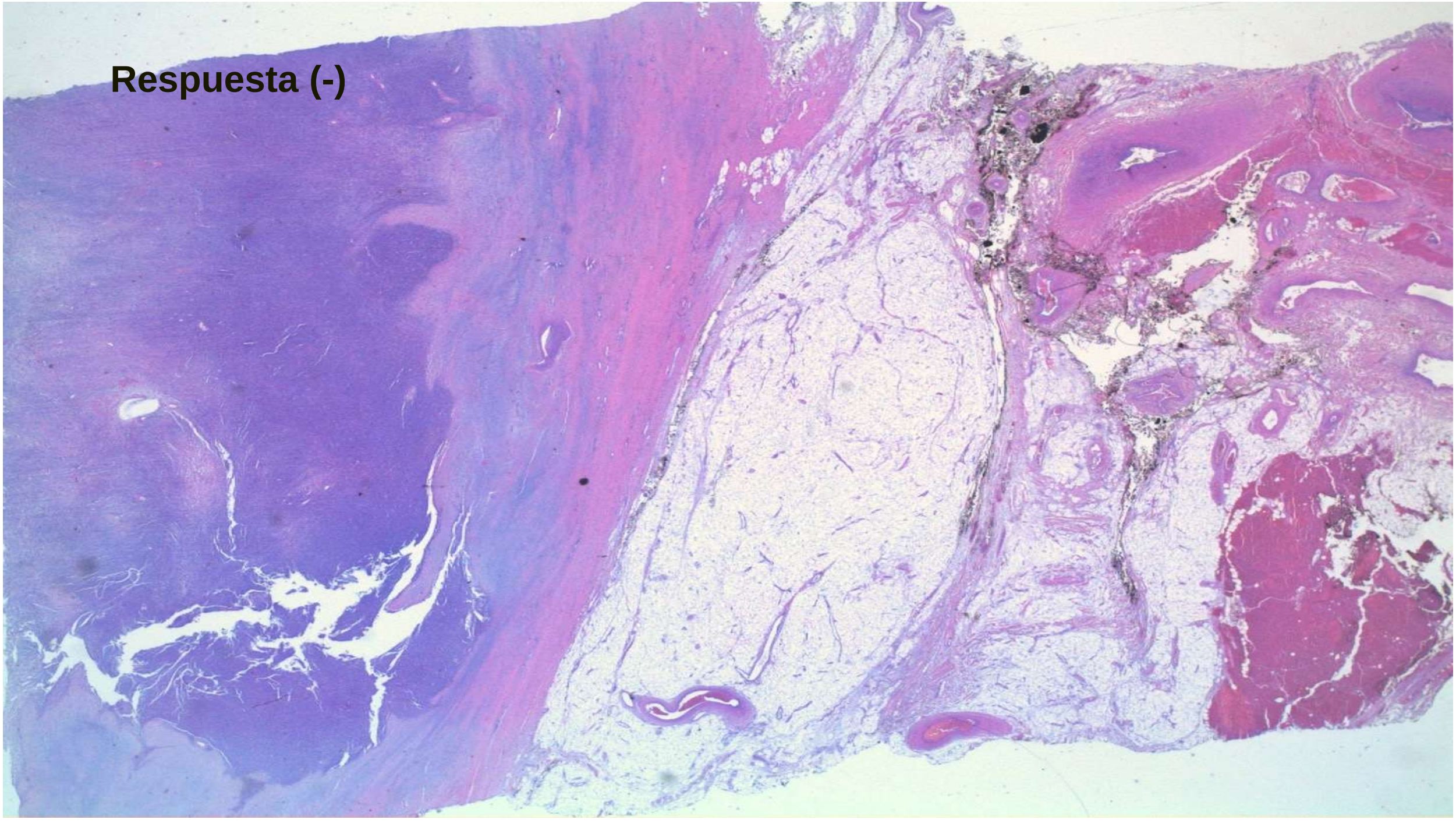
Respuesta (-)

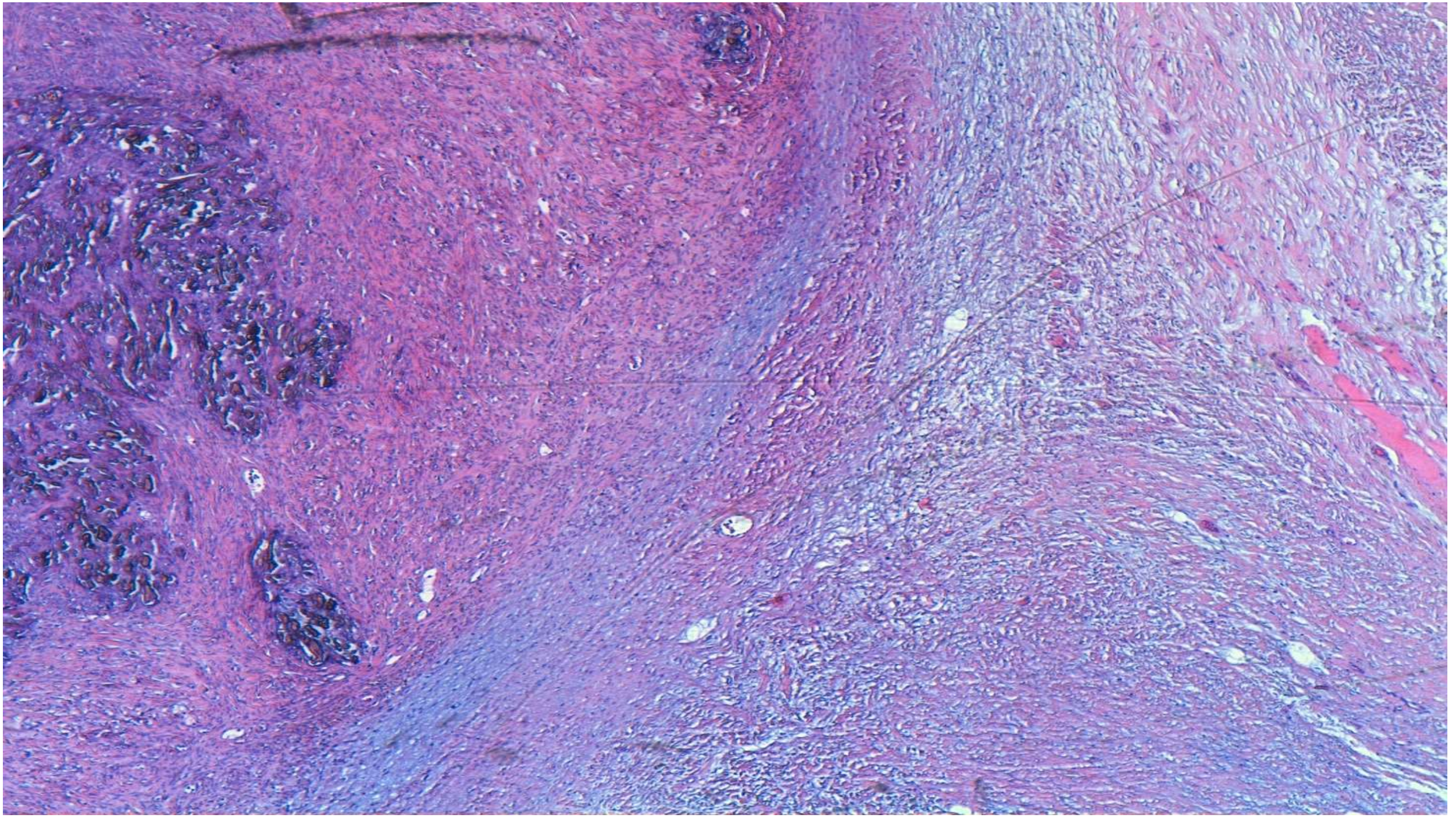

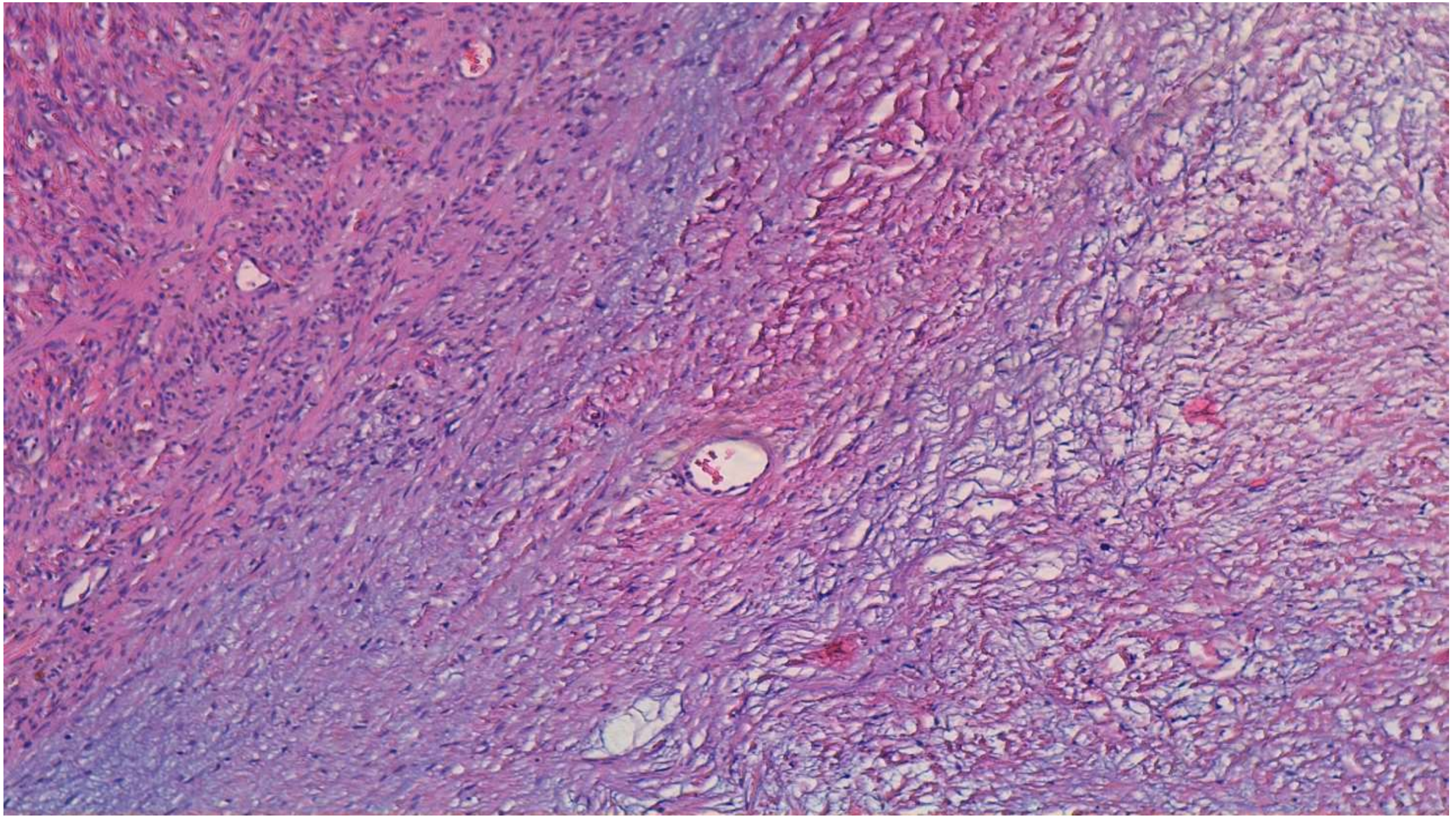

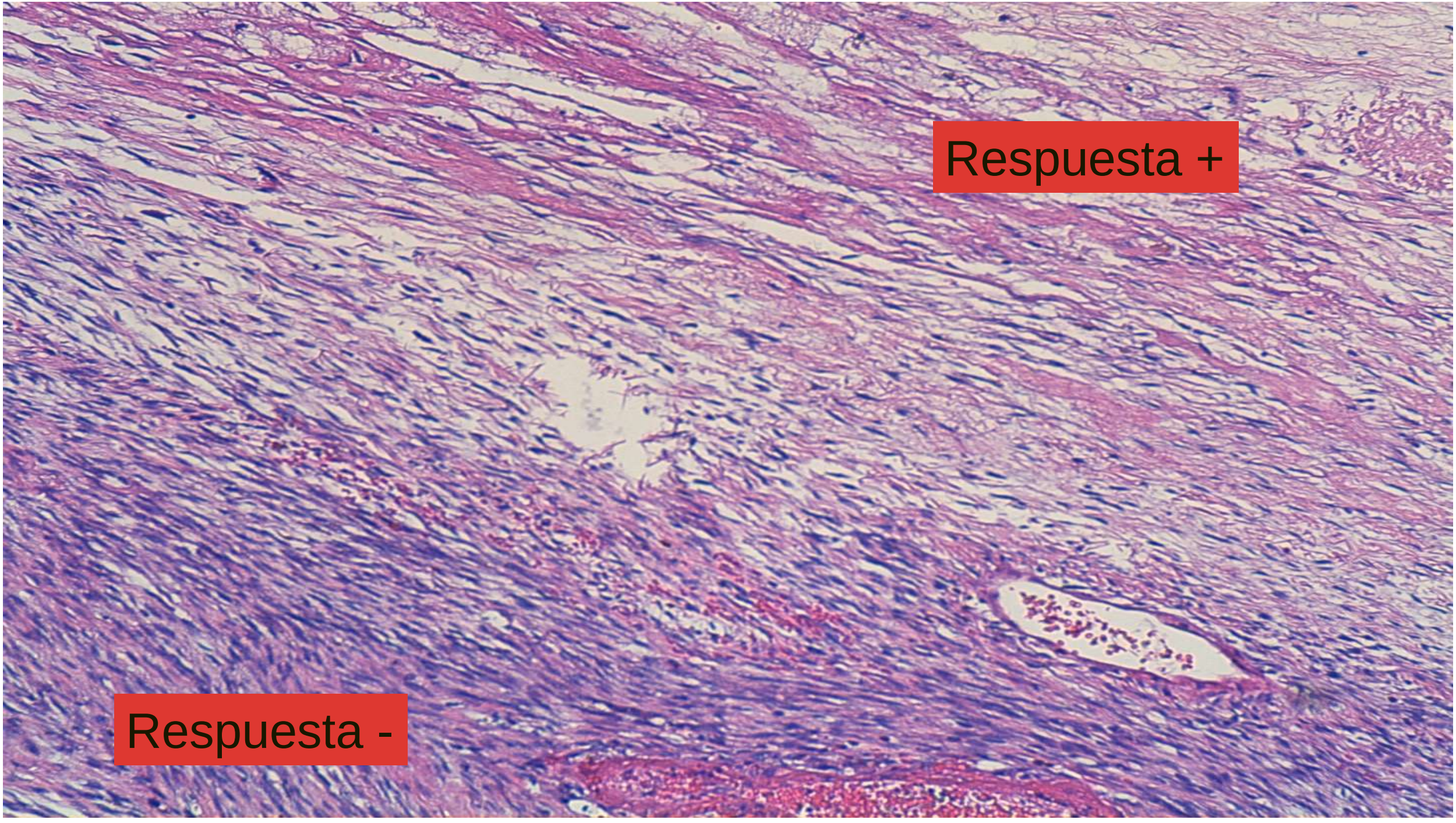
Respuesta +
Respuesta -

Informe patológico pieza quirúrgica post-neoadyuvancia

- **Sarcoma fusocelular, con rasgos morfológicos e inmunofenotípicos acordes con SARCOMA SINOVIAL MONOFASICO:**
  - **Patrón de crecimiento: Expansivo, no encapsulado, con márgenes infiltrativos (tejido fibroadiposo y muscular)**
  - **Diámetro mayor (post-QT): 17 cms**
  - **Patrón morfológico: fusocelular, monofásico, con leve menor atipia citológica y mayor patrón en "espina de pescado"**
  - **Cambios post-QT: Regresión parcial discreta, reflejada en áreas de fibrosis y fibroedema, alternando con áreas viables, con la morfología referida en el punto anterior (15-20%, de distribución irregular)**
  - **Márgenes quirúrgicos: libres (los menores son las secciones 18 y 20, correspondientes a margen superior y profundo, menores de 1 cm)**
  - **Inmunofenotipo: Similar al previo de la biopsia incisional , salvo el índice proliferativo, actualmente global del 10% (con áreas del 5% y otras incluso del 30% en zonas más viables/preservadas, y antes (biopsia previa) global, del 30%**
  - **Ampliacion de exéresis: Piel, celular subcutáneo y componente fascio-muscular con cambios fibrótico cicatriciales y signos de necrosis grasa en distintos estadíos evolutivos, en relación a cirugía previa. No se aprecian signos de infiltración neoplásica.**

Respuesta postratamiento

- Más que disminución de volumen:
  - Necrosis
  - Fibrosis
- %: 15-20%, de distribución irregular
  - Respuesta parcial discreta

9. CONTROL Y SEGUIMIENTO

SEGUIMIENTO

- Libre de recidiva neoplásica hasta el momento actual.
- Presentó un seroma intermuscular del compartimento adductor y edematización del tejido celular subcutáneo.
- Ultima RMN JUNIO 17: sin evidencia de recidiva.
- Ultimo TAC TAP 15/1/18: sin evidencia de enfermedad a distancia.
- 21/9/16: RTU por Carcinoma urotelial papilar de bajo grado de malignidad pT1 G2.

RNM Jun 2017

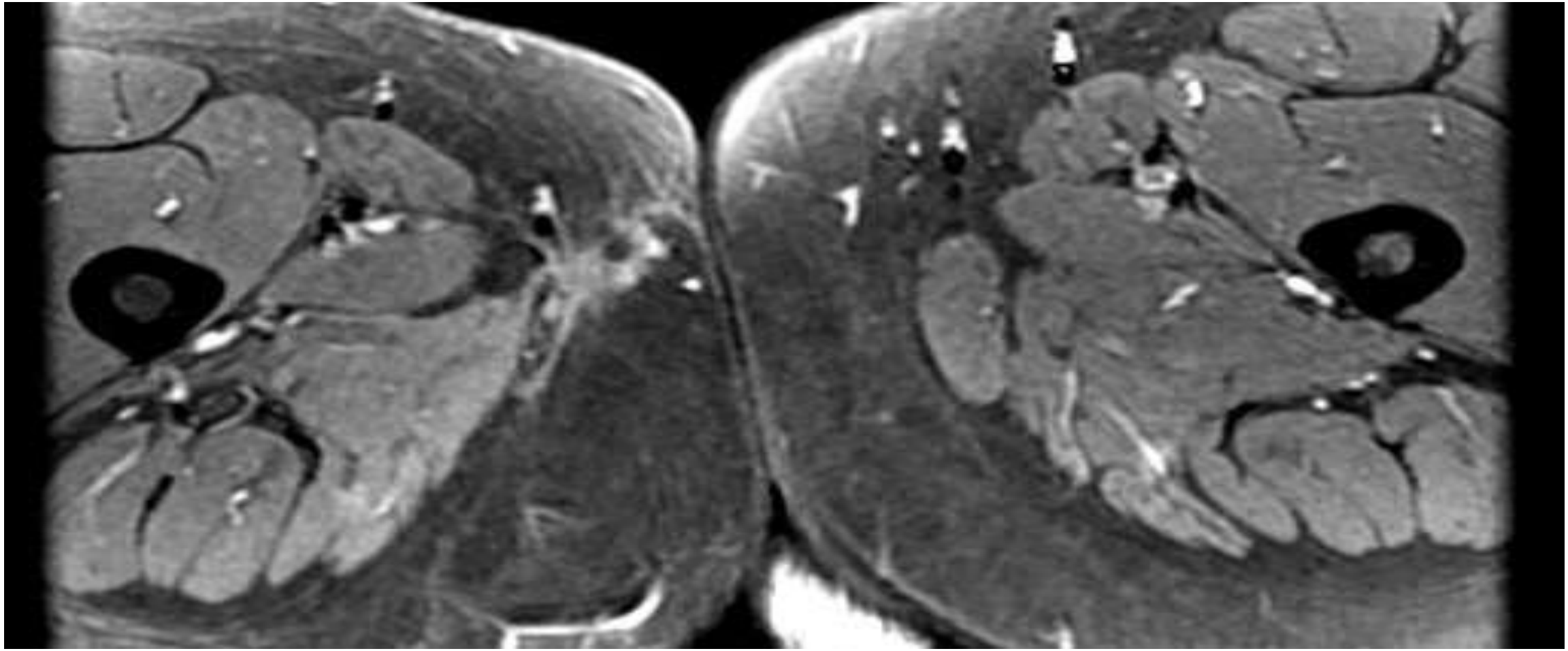

10. ALTERNATIVAS

PERFUSION AISLADA DE EXTREMIDAD CON HIPERTERMIA

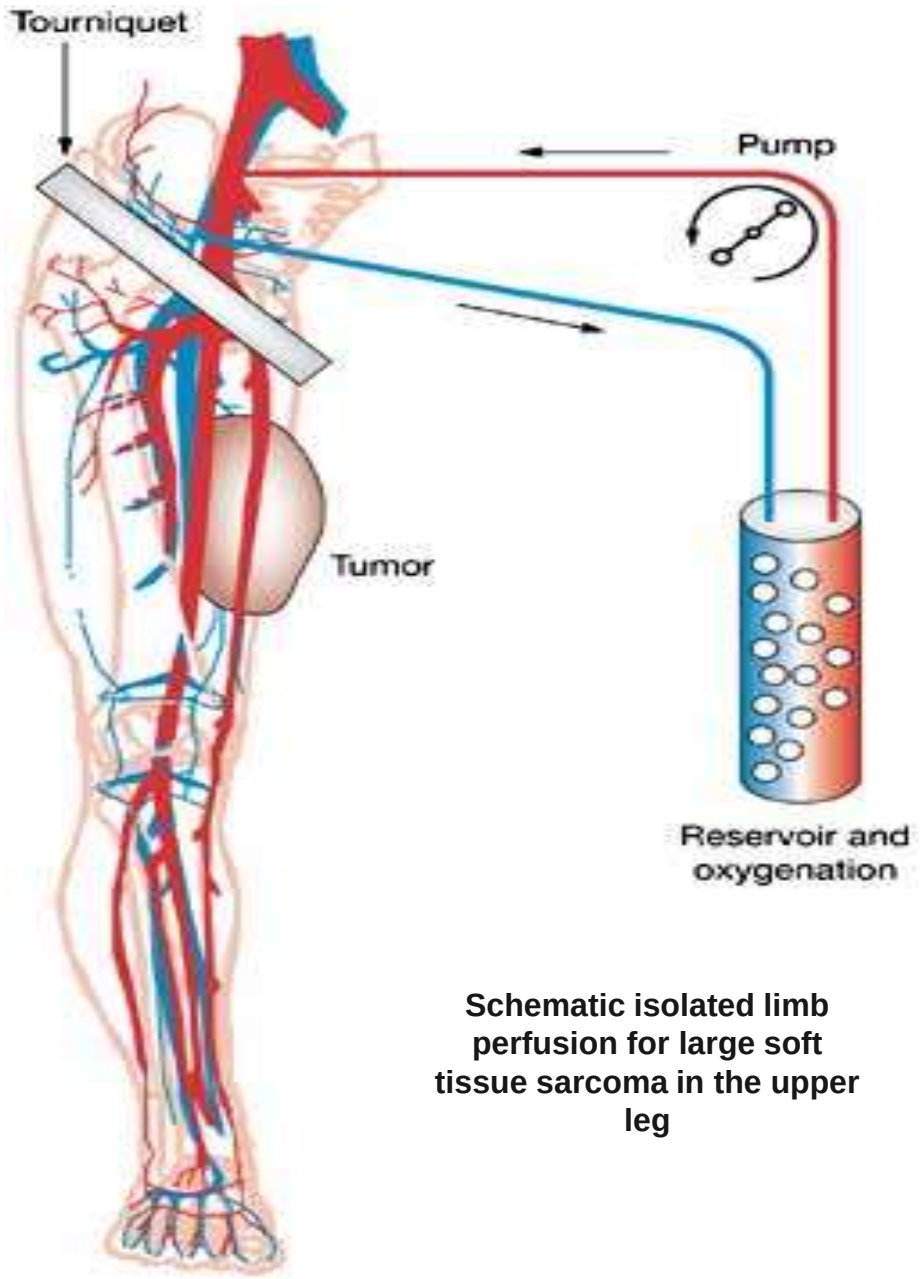

Schematic isolated limb perfusion for large soft tissue sarcoma in the upper leg

Grünhagen DJ et al. (2006) . Nat Clin Pract Oncol 3: 94–103

TABLE 1 Study cohort

Study	Year published	Location	Cohort size	Study type: P/R*	Primary tumor	Delivery method	Overall response rate	Complete response rate
Eroglu et al.	2000	Turkey	37	P	19 (51%)	ILP	79%	14%
Noorda et al.	2003	Netherlands	49	P	N/A	ILP	63%	8%
Hegazy et al.	2007	Egypt	40	P	28 (70%)	ILI + RT	85%	55%
Hayes et al.	2007	United Kingdom	16	P	8 (50%)	ILP	53%	3%
Pennacchioli et al.	2007	Italy	88	P	N/A	ILP	91%	28%
Cherix et al.	2008	Switzerland	51	R	38 (75%)	ILP	66%	13%
Moncrieff et al.	2008	Australia	21	P	14 (67%)	ILI	90%	57%
Bonvalot et al.	2009	France	100	P	48 (48%)	ILP	79%	30%
Nachmany et al.	2009	Israel	43	R	N/A	ILP	31%, 65%*	15%, 44%*
Grabellus et al.	2011	Germany	53	P	29 (55%)	ILP	53%	17%
Hoven-Gondrie	2011	Netherlands	102	P	86 (88%)	ILP	77%	22%
Turaga et al.	2011	USA	14	R	N/A	ILI	80%	30%
Wray et al.	2011	USA	27	P	N/A	ILP	20%, 64%†	0%, 12%†
Olofsson et al.	2012	Sweden	52	P	32 (59.3)	ILP	71%	21%
Jakob et al.	2014	Germany	90	P	70 (78%)	ILP	90%	37%
Smith et al.	2015	United Kingdom	36	P	N/A	ILP	61%	22%
Deroose et al.	2015	France	275	P	179 (58%)	ILP	69%	17%
Rastrelli et al.	2016	Italy	117	R	92 (79%)	ILP	76%	47%
Mullinax et al.	2017	USA	77	R	N/A	ILI	58%	30%

Neuwirth MG, Ann Surg Oncol. 2017 Dec;24(13):3803-3810.

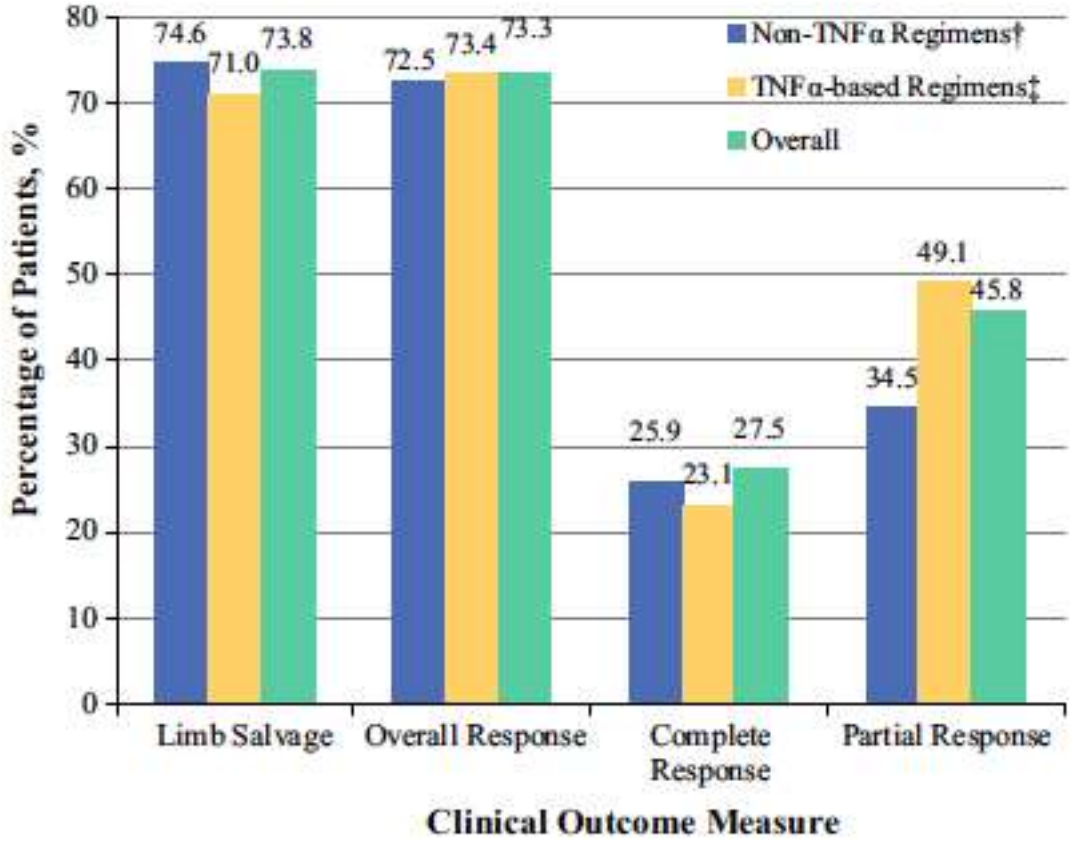

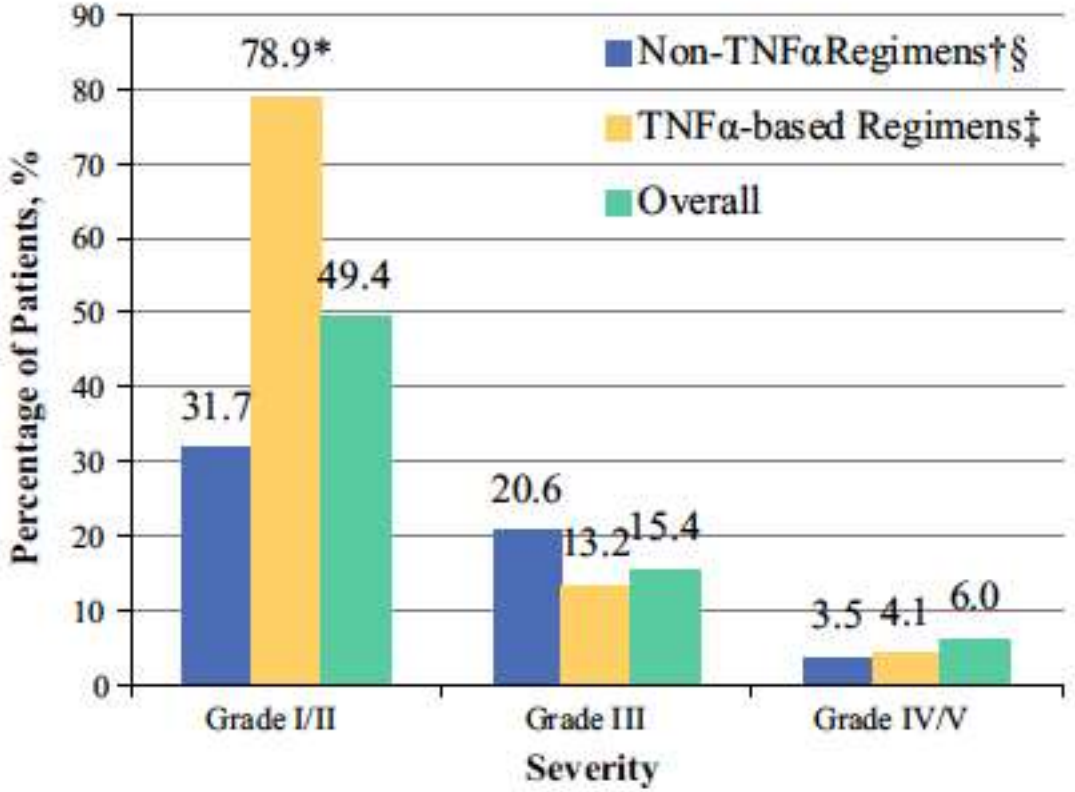

Neuwirth MG, Ann Surg Oncol. 2017 Dec;24(13):3803-3810.

Table 2 Post-operative outcomes in standard and ILP cohorts

	Standard N = 80	ILP N = 44	p value
Complications			
All	25 (31%)	17 (39%)	0.43
Wound infection	12 (15%)	7 (16%)	1.0
Collection	13 (16%)	8 (18%)	0.81
Amputation	0 (0%)	2 (5%)	0.12
Resection margin			
R0	65 (81%)	39 (89%)	0.32
R1	15 (19%)	5 (11%)	
Follow-up, months			
Median	31	36	0.3373
(Range)	(4–194)	(8–163)	
Local recurrence	13 (16%)	5 (11%)	0.597
Local recurrence OR post-operative amputation	13 (16%)	7 (16%)	1
Systemic recurrence	43 (54%)	23 (52%)	1

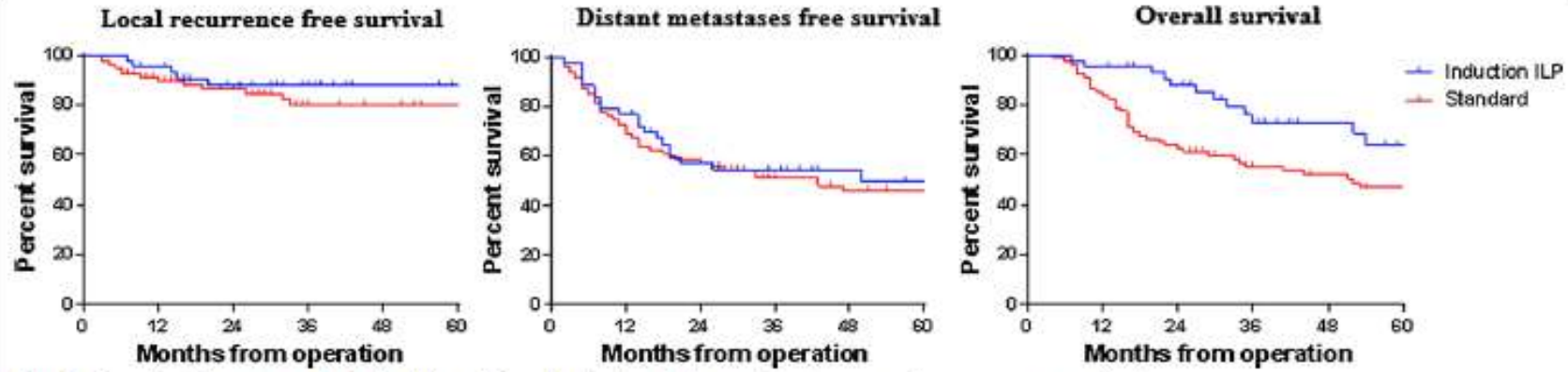

Fig. 3 Oncological outcomes for the ILP and Standard cohorts (logrank test was used to assess comparison)

Jakob J, Clin Sarcoma Res. 2018 Jul 2;8:12.