GEIS XX
International Symposium
Málaga, October 6th – 8th, 2022

Pathology Workshop

José M. Mellado Soria
Hospital Regional Universitario – Málaga – Servicio Andaluz de Salud
analizA

Conflictos de interés

analizA

MDM2 en “OTRAS” neoplasias

Caso de 2017:

Zona perirrenal: MIOPERICITOMATOSIS (cosa excepcional)

No se hizo MDM2 ni otros marcadores

Evoluciona y caso en verano 2022:

Zona perirrenal, que pasa a zona peridiafragmática-pulmonar

DERMATOFIBROMA PROFUNDO BENIGNO

Curiosidad: MDM2 y CDK4 positivas (inmunohistoquímica)

MDM2 en “OTRAS” neoplasias

¿Qué te parece esto?

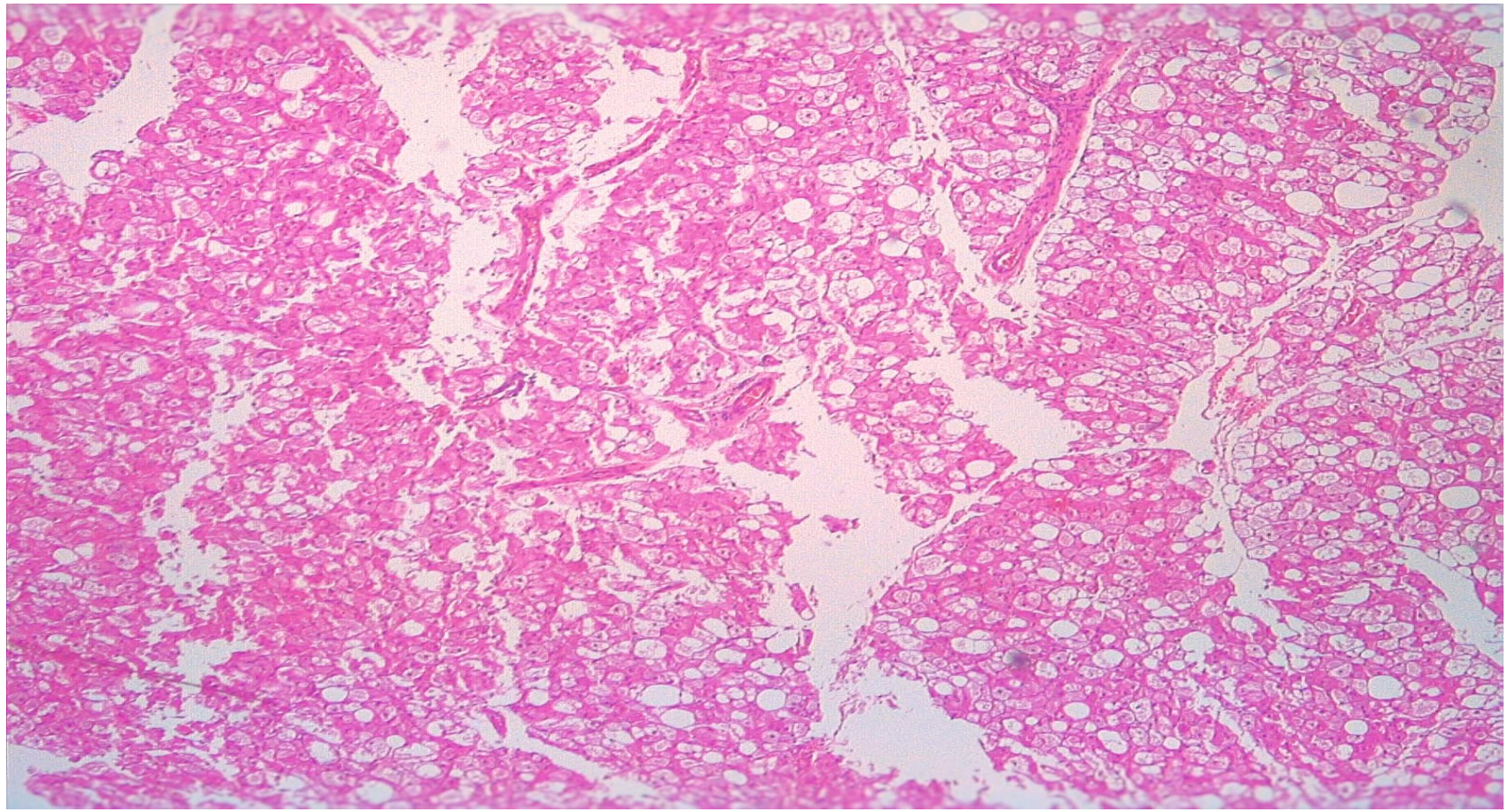

MDM2 en “OTRAS” neoplasias

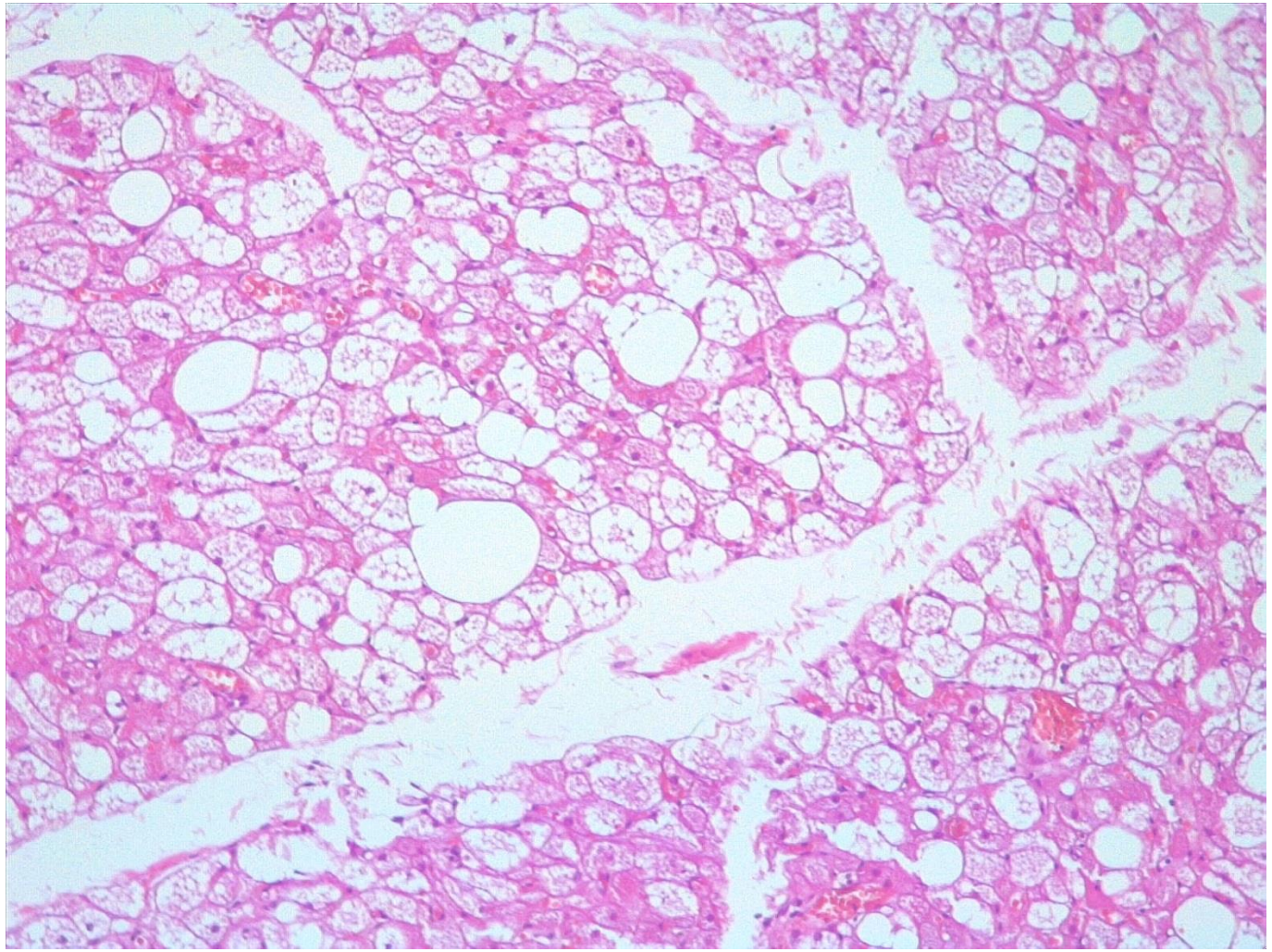

MDM2 en “OTRAS” neoplasias

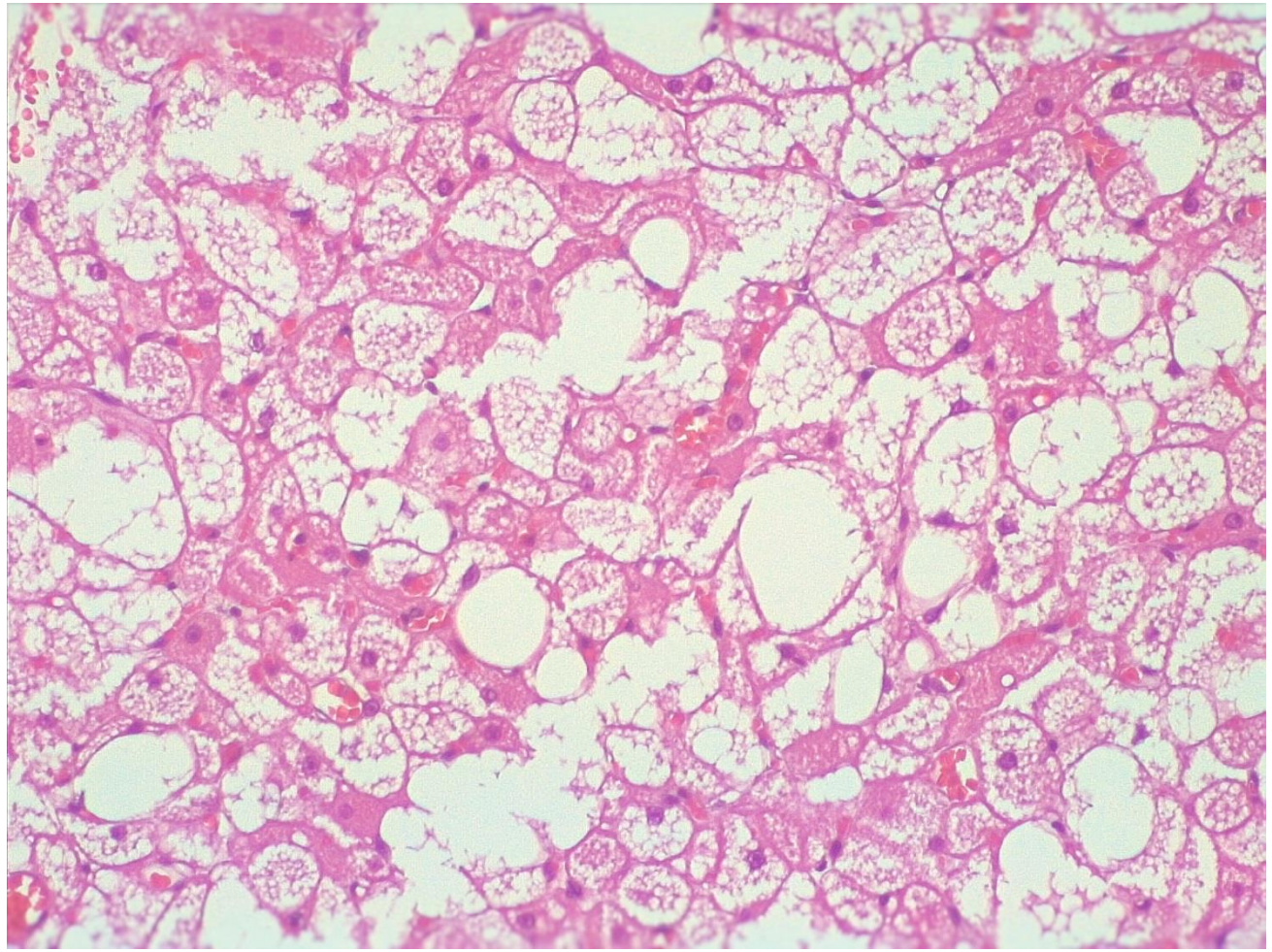

MDM2 en “OTRAS” neoplasias

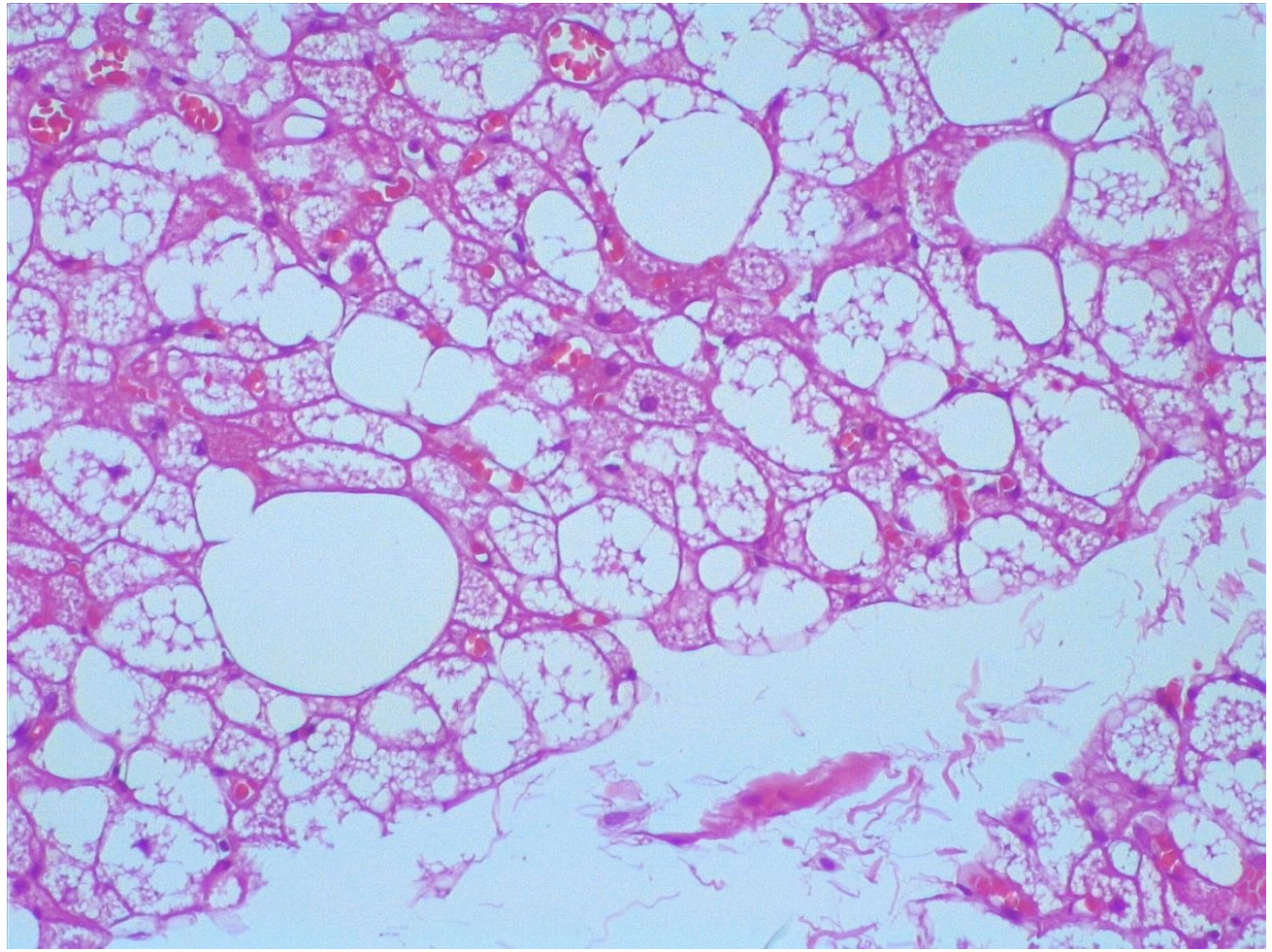

MDM2 en “OTRAS” neoplasias

HIBERNOMA

Tumor benigno con células adiposas granulares eosinofílicas multivacuoladas con núcleos normocrómicos centrales pequeños

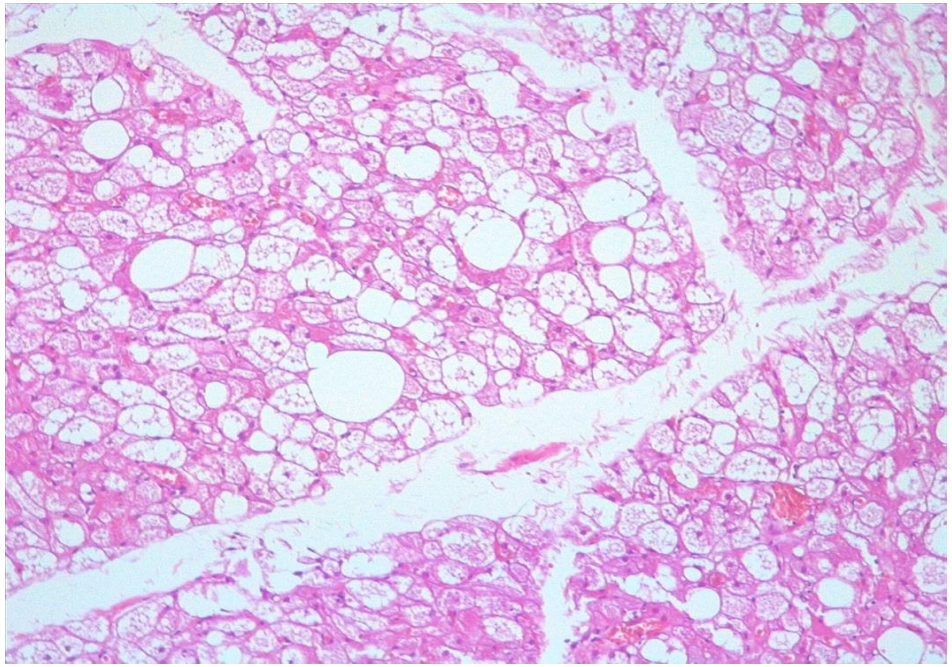

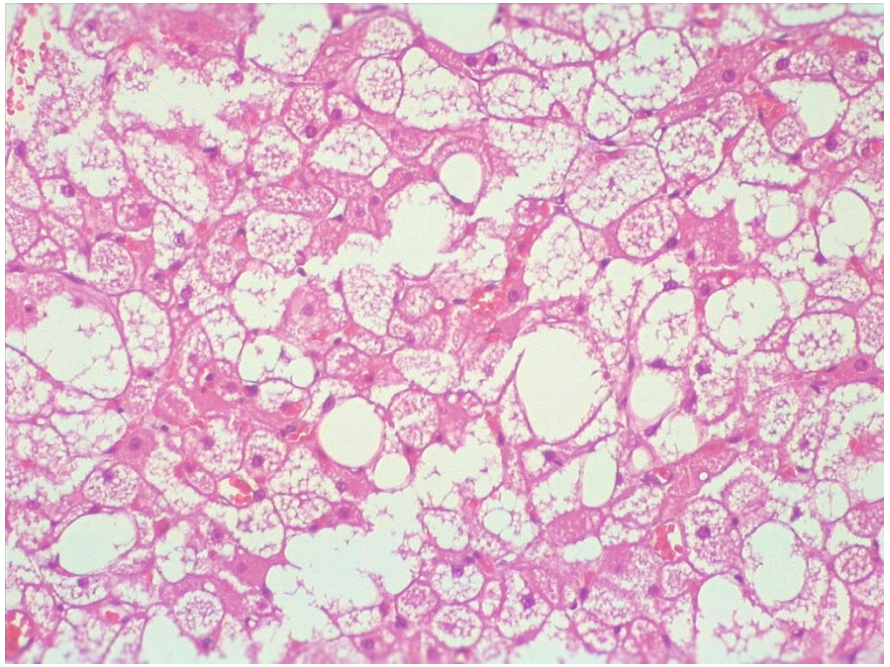

MDM2 en “OTRAS” neoplasias

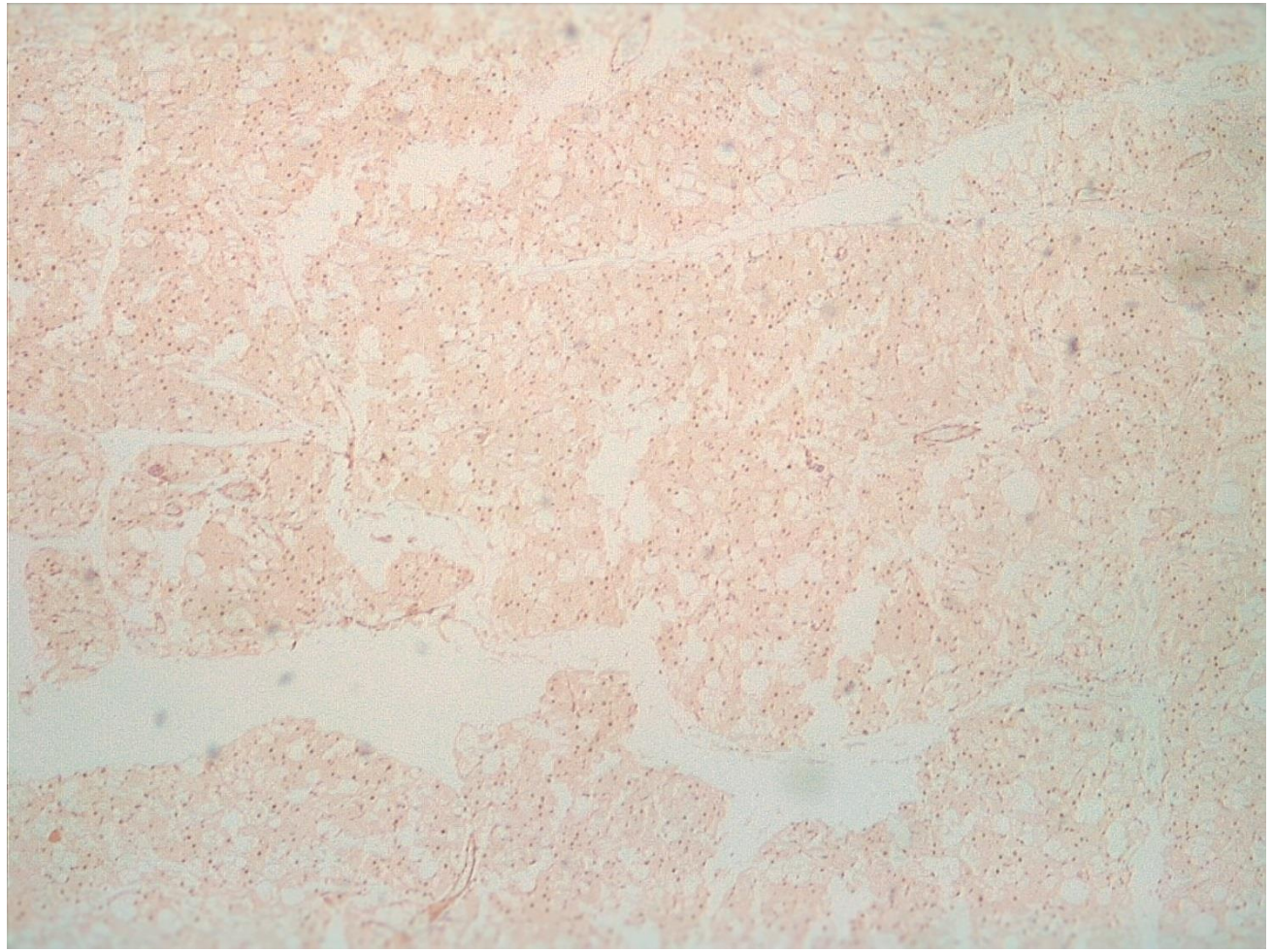

MDM2 en “OTRAS” neoplasias

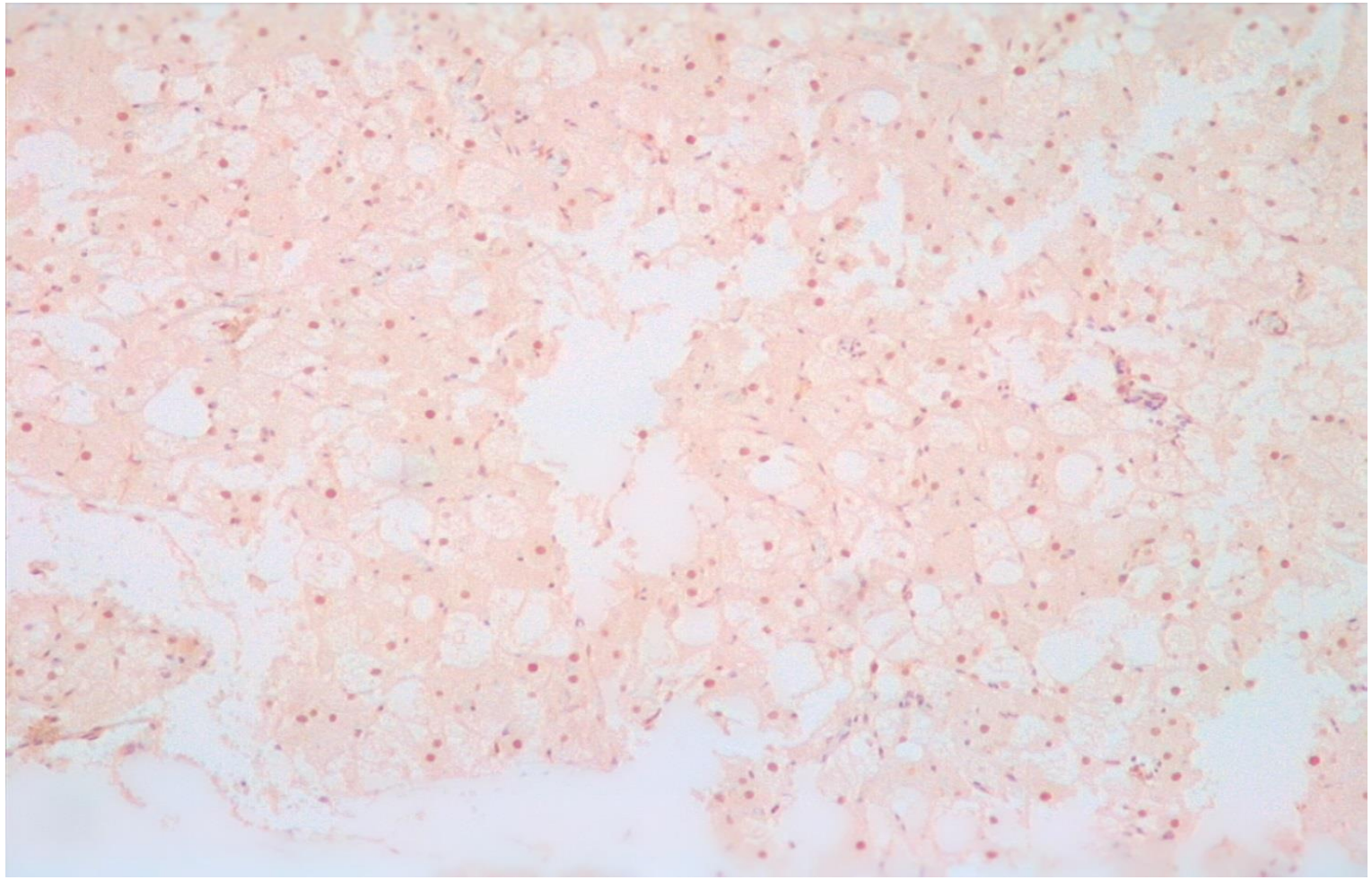

MDM2 en “OTRAS” neoplasias

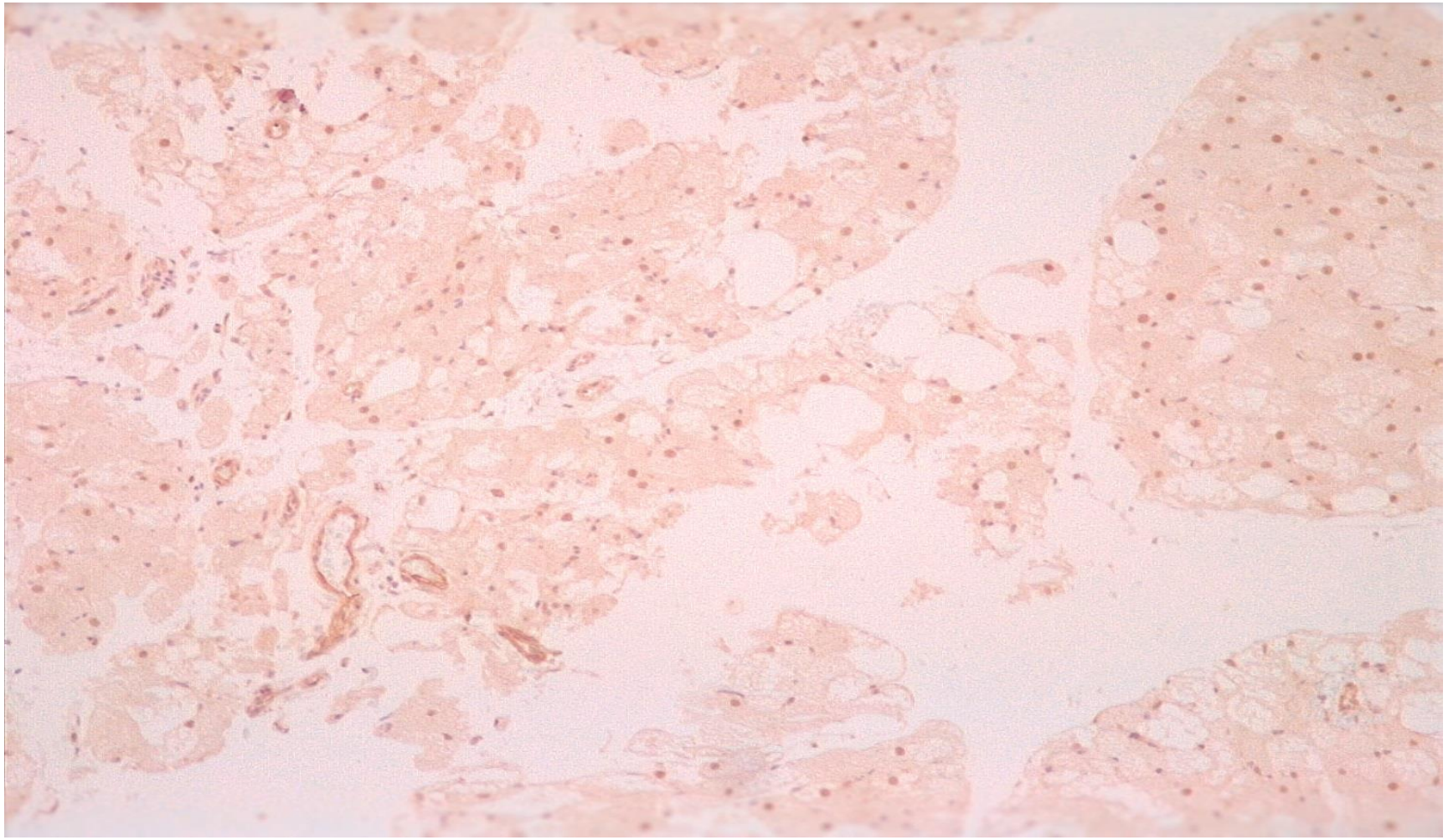

MDM2 en “OTRAS” neoplasias

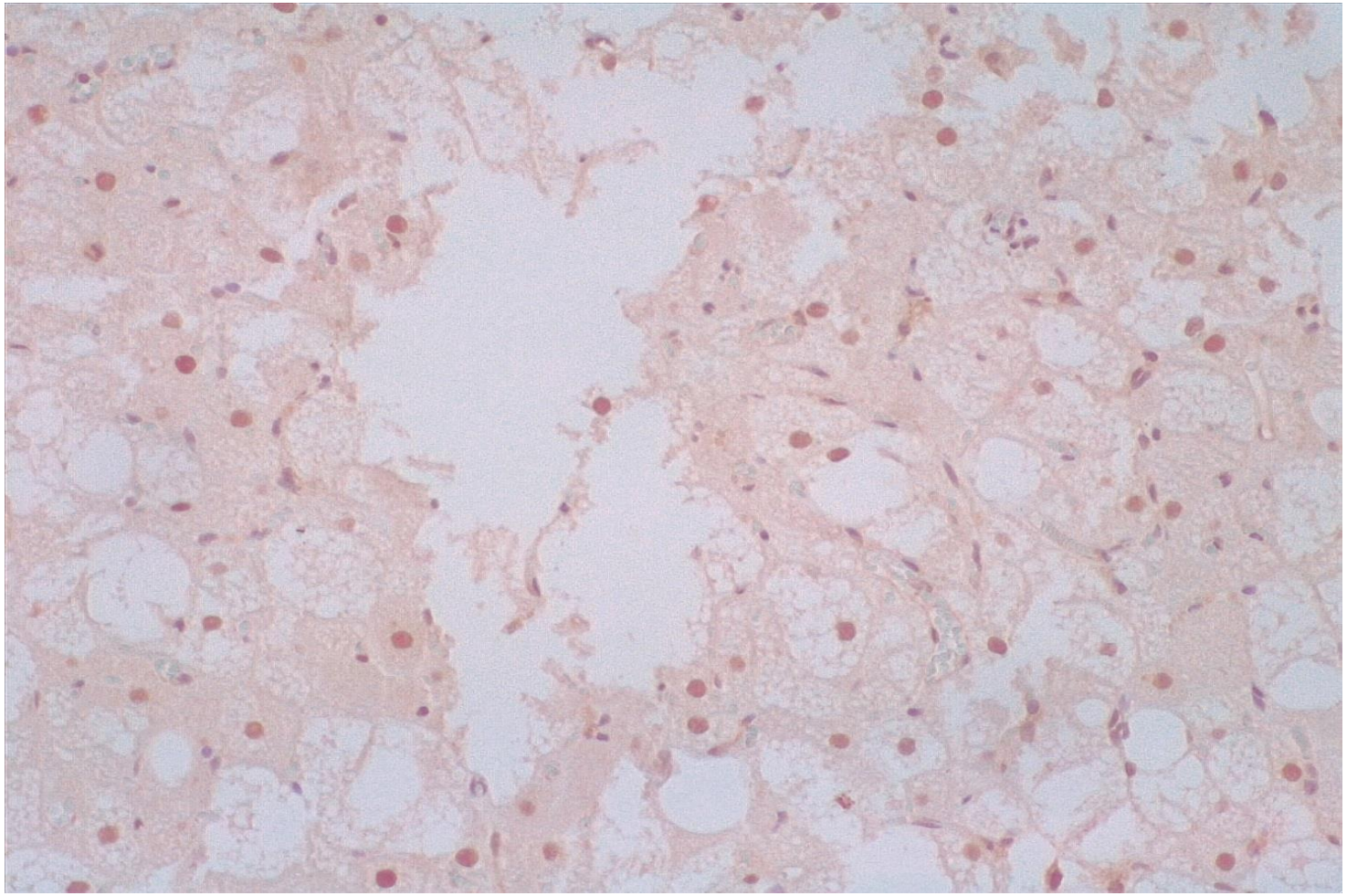

MDM2 en “OTRAS” neoplasias

Virchows Archiv (2021) 478:527–534
https://doi.org/10.1007/s00428-020-02914-5

ORIGINAL ARTICLE

Check for updates

Nuclear expression of MDM2 in hibernoma: a potential diagnostic pitfall

Yojiro Tsuda[1] · Atsuji Matsuyama[1] · Kosuke Makihara[2] · Koichi Higaki[3] · Toru Motoi[4] · Tomotake Okuma[5] · Masanori Hisaoka[1]

Received: 29 May 2020 / Revised: 31 July 2020 / Accepted: 14 August 2020 / Published online: 20 August 2020

Abstract
Hibernoma is a rare benign adipocytic tumor composed of a proliferation of brown and white fat cells varying in their proportions. The tumor may also contain fat cells resembling lipoblasts, which makes it difficult to distinguish it from atypical lipomatous tumor/well differentiated liposarcoma (ALT/WDLS). Although nuclear expressions of murine double minute 2 (MDM2) and cyclin-dependent kinase 4 (CDK4) are widely used as immunohistochemical surrogate markers for ALT/WDLS, the utility of these proteins in distinguishing between hibernoma and ALT/WDLS still remains to be elucidated. We evaluated immunohistochemical expressions of MDM2 and CDK4 in 10 hibernomas expressing uncoupling protein-1 (UCP-1), a mitochondrial protein transporter consistently expressed in brown fat cells, and lacking *MDM2* gene amplification, which was analyzed by fluorescence in situ hybridization (FISH). In contrast to the data previously obtained, nuclear expression of MDM2 was observed in 100% (10/10 cases) of the hibernomas irrespective of the proportion of brown fat cells, whereas no cases were positive for CDK4. The tumors also showed almost concurrent expression of p53 (in 9/10 cases) and ubiquitin-specific-processing protease 7 (USP7) (in 10/10 cases), which deubiquitinates and stabilizes MDM2, potentially resulting in its nuclear expression without *MDM2* gene amplification. MDM2 expression may thus be a diagnostic pitfall for hibernoma particularly in differentiating it from ALT/WDLS.

Keywords Hibernoma · MDM2 · Atypical lipomatous tumor/well differentiated liposarcoma · Immunohistochemical pitfalls · FISH

Introduction

Hibernoma is a rare, benign adipocytic tumor displaying brown fat differentiation. It commonly arises in young or middle-aged adults as a slowly growing, small subcutaneous mass located mainly in the thigh, trunk, chest wall, upper extremity, or head and neck [1]. Some hibernomas show a large tumor size of more than 10 cm and are deeply seated in the abdominal cavity or retroperitoneum [1, 2]. Hibernoma is composed of fat cells identical to brown adipocytes having eosinophilic, granular, or multivacuolated cytoplasm and small, round, and centrally located nuclei, variably admixed with univacuolated white fat cells, and that are arranged in sheets or lobules with a rich capillary network [1]. The morphology of hibernoma is distinct and can be readily differentiated from those of other adipocytic tumors without any ancillary techniques, such as immunohistochemistry. However, a subset of hibernomas predominantly contains multivacuolated lipoblast-like cells, which may be confused

This article is part of the Topical Collection on *Quality in Pathology*

✉ Yojiro Tsuda
yojiro-t@med.uoeh-u.ac.jp

1 Department of Pathology and Oncology, School of Medicine, University of Occupational and Environmental Health, 1-1 Iseigaoka, Yahatanishi-Ku, Kitakyushu 807-8555, Japan
2 Department of Surgical Pathology, Kyushu Rosai Hospital, Kitakyushu 800-0296, Japan
3 Division of Pathology, St Mary Hospital, Kurume 830-8543, Japan
4 Department of Pathology, Tokyo Metropolitan Cancer and Infectious Diseases Center Komagome Hospital, Tokyo 113-8677, Japan
5 Department of Orthopedic Surgery and Musculoskeletal Oncology, Tokyo Metropolitan Cancer and Infectious Diseases Center Komagome Hospital, Tokyo 113-8677, Japan

Virchows Arch. 2021 Mar;478(3):527-534. doi: 10.1007/s00428-020-02914-5. Epub 2020 Aug 20.

Nuclear expression of MDM2 in hibernoma: a potential diagnostic pitfall

Yojiro Tsuda 1, Atsuji Matsuyama 2, Kosuke Makihara 3, Koichi Higaki 4, Toru Motoi 5, Tomotake Okuma 6, Masanori Hisaoka 2

Department of Pathology and Oncology, School of Medicine, University of Occupational and Environmental Health, 1-1 Iseigaoka, Yahatanishi-Ku, Kitakyushu, 807-8555, Japan. yojiro-t@med.uoeh-u.ac.jp

MDM2 en “OTRAS” neoplasias

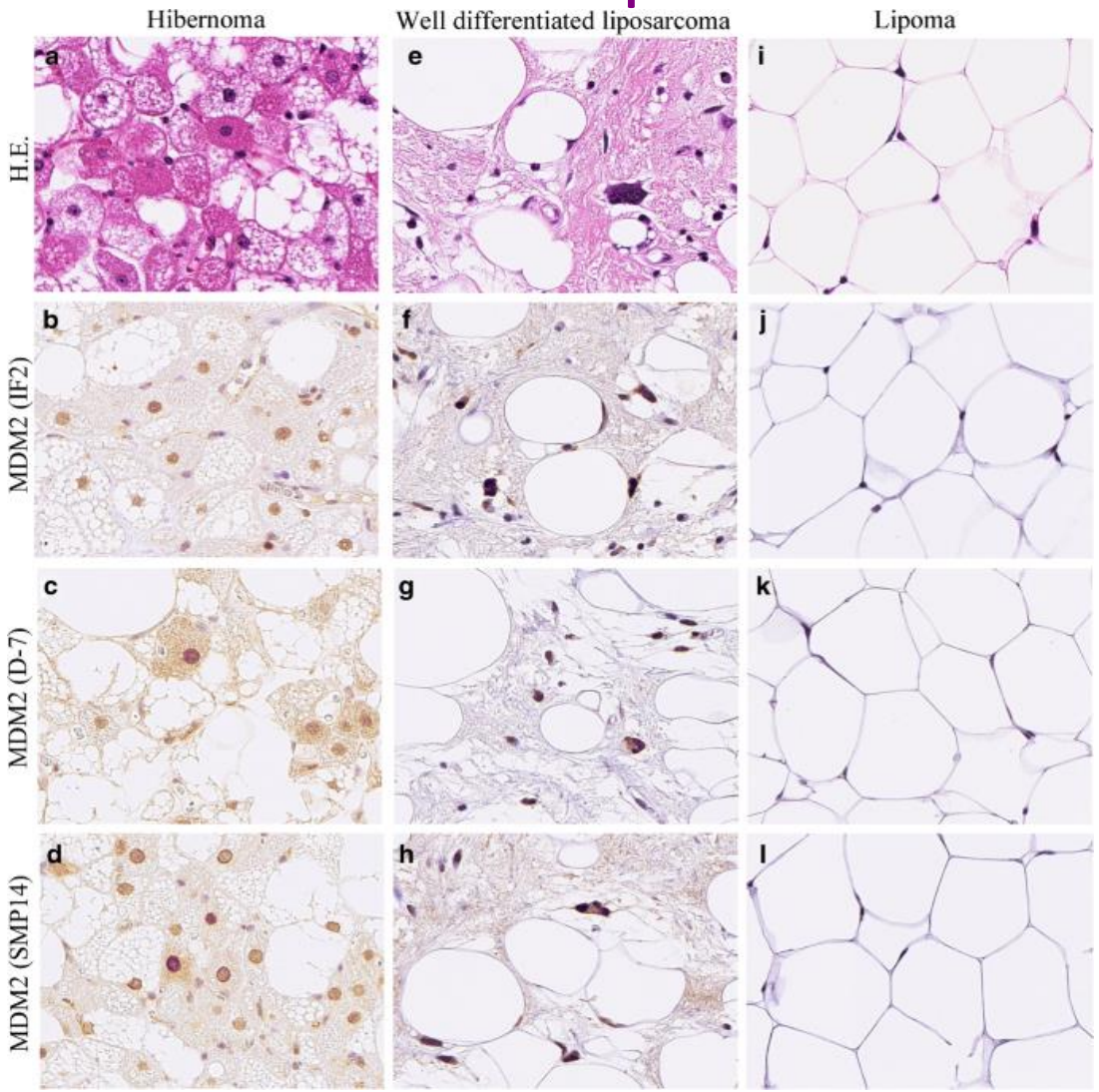

MDM2 en “OTRAS” neoplasias

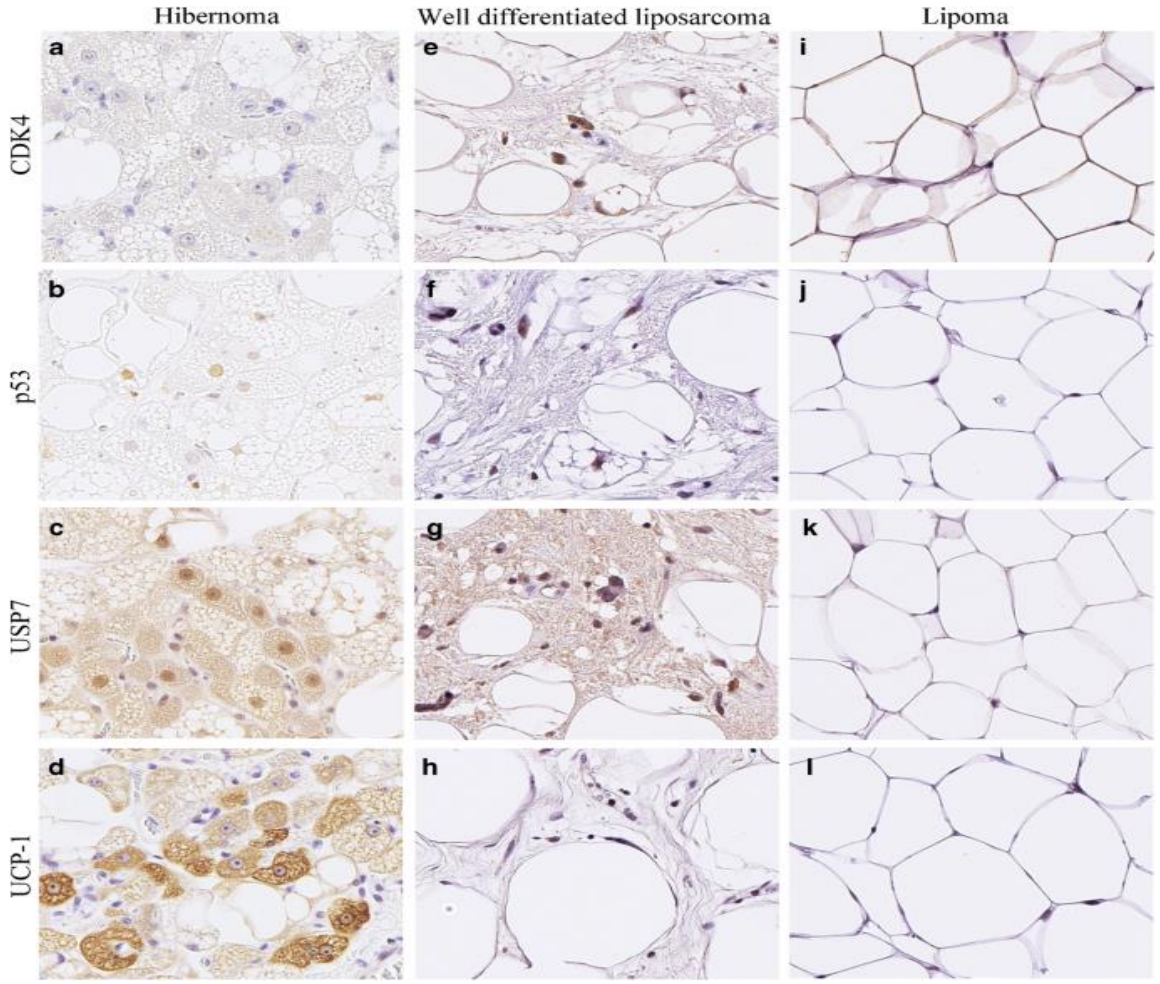

MDM2 en “OTRAS” neoplasias

We evaluated immunohistochemical expressions of MDM2 and CDK4 in 10 hibernomas expressing uncoupling protein-1 (UCP-1), a mitochondrial protein transporter consistently expressed in brown fat cells, and **lacking MDM2 gene amplification**, which was analyzed by fluorescence in situ hybridization (**FISH**).

MDM2 en “OTRAS” neoplasias

In contrast to the data previously obtained, ***nuclear expression of MDM2 was observed in 100% (10/10 cases)*** of the hibernomas irrespective of the proportion of brown fat cells, whereas ***no cases were positive for CDK4.***

MDM2 en “OTRAS” neoplasias

The tumors also showed almost concurrent expression of p53 (in 9/10 cases) and **ubiquitin-specific- processing protease 7** (USP7) (in 10/10 cases), **which deubiquitinates and stabilizes MDM2**, potentially resulting in its **nuclear expression *without* MDM2 gene amplification**.

MDM2 expression may thus be a diagnostic pitfall for hibernoma particularly in differentiating it from ALT/WDLS

MDM2 en “OTRAS” neoplasias

- Yoest J, Sadri N. MDM2. PathologyOutlines.com website. https://www.pathologyoutlines.com/topic/stainsmdm2.html. Accessed October 5th, 2022
- Murine Double Minute 2
- Ubicado en 12q15
- Codifica la proteína que inhibe p53
- Amplificado en varios tumores malignos

MDM2 en “OTRAS” neoplasias

- *MDM2* amplificado en el anillo supernumerario o cromosomas marcadores en muchos tumores, lo que lleva a la **supresión de p53**
- Frecuente en **tumor lipomatoso atípico/liposarcoma bien diferenciado y liposarcoma desdiferenciado**; a menudo se usa para distinguir estas entidades de los imitadores
- Distinguir el **osteosarcoma de bajo grado y el osteosarcoma parosteal** (positivo) de las lesiones fibrosas y fibroóseas benignas (negativo)
- Sarcoma intimal; rabdomiosarcoma esclerosante (algunos casos).
- Comúnmente probado por **FISH o IHC**, también hibridación in situ cromogénica de doble color (**DISH / CISH**); FISH ampliamente aceptado como **gold standard**

MDM2 en “OTRAS” neoplasias

TINCIÓN NEGATIVA

- Tumores adiposos benignos, sarcomas pobremente diferenciados (Virchows Arch 2010;456:167)
- Tumor lipomatoso pleomórfico/células fusiformes atípico (puede verse polisomía 12) (Virchows Arch 2020;476:29 , Virchows Arch 2010;456:167 , Am J Surg Pathol 2017;41:234)
- Liposarcoma mixoide (rara vez positivo), liposarcoma pleomórfico, liposarcoma mixoide pleomórfico (Virchows Arch 2020;476:29 , Virchows Arch 2010;456:167)
- Osteosarcoma perióstico (Hum Pathol 2015;46:549)
- Lesiones fibrosas y fibroóseas benignas (displasia fibrosa, miositis osificante, periostitis reactiva, osteocondroma, otras) (Mod Pathol 2010;23:1279)
- Liposarcoma pleomórfico de piel/subcutis por lo general (Am J Surg Pathol 2012;36:1047)
- Neurofibroma (Arch Pathol Lab Med 2012;136:95)
- Schwannoma (MDM2 gana en el 15 % de los schwannomas vestibulares pero sin amplificaciones) (Eur Arch Otorhinolaryngol 2013;270:2433)
- Rabdomiosarcoma, pediátrico (Sarcoma 2012;2012:492086)
- Tumor maligno de la vaina del nervio periférico - la positividad varía: amplificación detectada en 6 - 20 % (Arch Pathol Lab Med 2012;136:95 , Mod Pathol 2018;31:1694 , JCO Precis Oncol 2018;2018:PO.17.00235)
    - Tinción IHC focal / débil / moderada (10 %) o fuerte (26 %) correspondiente a polisomía / ganancia débil / amplificación débil (34 %) o amplificación de alto nivel (1,5 %) por FISH (se recomienda H3K27me3 IHC en su lugar) (Am J Surg Pathol 2018;42:656)
- Angiosarcoma (Cardiovasc Pathol 2019;43:107142)
- Carcinoma sarcomatoide pulmonar 14% (Cardiovasc Pathol 2019;43:107142)
- Mixofibrosarcoma (Virchows Arch 2010;456:167)
- Sarcomas fibromixoides de bajo grado (Virchows Arch 2010;456:167)

MDM2 en “OTRAS” neoplasias

TINCIÓN NEGATIVA

- Adenocarcinoma de vesícula biliar (11,2 %), carcinoma adenoescamoso de pulmón (9,8 %), glioblastoma (7,2 - 8,2 %), carcinoma urotelial (2,9 - 10,4 %), adenocarcinoma duodenal (7,8 %), carcinosarcoma de ovario (7,8 %) (Cold Spring Harb Perspect Med 2016;6:a026336 , JCO Precis Oncol 2018;2018:PO.17.00235)
- Glándula suprarrenal: carcinoma adrenocortical (1,1 %), feocromocitoma (Cold Spring Harb Perspect Med 2016;6:a026336)
- Cerebro: astrocitomas (no glioblastoma multiforme) (0,4 %) (Cold Spring Harb Perspect Med 2016;6:a026336)
- Mama: carcinoma invasivo (0,9%) (Cold Spring Harb Perspect Med 2016;6:a026336)
- Tracto gastrointestinal: colangiocarcinoma (2,8 %), adenocarcinoma colorrectal, carcinoma esofágico, adenocarcinoma gástrico (1,6 - 5,5 %), carcinoma hepatocelular, adenocarcinoma pancreático (Cold Spring Harb Perspect Med 2016;6:a026336 , JCO Precis Oncol 2018;2018:PO. 17.00235)
- Genitourinario: carcinoma de células renales de células claras, carcinoma de células renales papilares, carcinoma de células renales cromófobas, adenocarcinoma de próstata, tumores de células germinales testiculares (1,3%) (Cold Spring Harb Perspect Med 2016;6:a026336)
- Ginecológicos: carcinoma endometrial, cistoadenocarcinoma seroso de ovario (0,3 %), carcinoma escamoso de cuello uterino (0,3 %), carcinosarcoma uterino (Cold Spring Harb Perspect Med 2016;6:a026336)
- Cabeza y cuello: carcinoma de células escamosas (Cold Spring Harb Perspect Med 2016;6:a026336)
- Hematolinfoide: linfoma difuso de células B grandes (Cold Spring Harb Perspect Med 2016;6:a026336)
- Pulmón: adenocarcinoma (0,9 - 5,6 %), carcinoma de células escamosas (0,2 %), mesotelioma (JCO Precis Oncol 2018;2018:PO.17.00235 , Cold Spring Harb Perspect Med 2016;6:a026336)
- Piel: melanoma cutáneo (Cold Spring Harb Perspect Med 2016;6:a026336)
- Tiroides: carcinoma de tiroides (Cold Spring Harb Perspect Med 2016;6:a026336)

GRACIAS

Jose Mellado
mesola@hotmail.com

Junta de Andalucía | Consejería de Salud y Consumo | Servicio Andaluz de Salud

josem.mellado.sspa@juntadeandalucia.es

analizA

jmellado@analizalab.com